

Giant Antrochoanal Polyp in a Six-years-old Boy: A Case Report and Literature Review

Raid M. Al-Ani*

Department of Surgery/Otolaryngology, College of Medicine, University of Anbar, Ramadi, Anbar, Iraq.

(Received : 9 December 2021; Accepted : 1 April 2022; First published online: 15 May 2022)

ABSTRACT

Antrochoanal polyps are more prevalent in children than adults. Unilateral nasal obstruction and rhinorrhea are usually the features of unilateral antrochoanal polyps. Bilateral nasal obstruction can be a feature of antrochoanal polyp if it is large and obstruct both choanae. The giant antrochoanal polyp is rarely reported in the literature. We are reporting this scenario of giant left antrochoanal polyp in a 6-years-old boy who presented with bilateral nasal obstruction, nasal and postnasal mucopurulent discharge, hypo-nasal speech, mouth breathing, snoring, and obstructive sleep apnea syndrome. The physical examination revealed a mass seen in the oropharynx behind the uvula. Further examination by nasal endoscopy, computerized tomography, and histopathological evaluation of the excised polyp have confirmed the diagnosis of an antrochoanal polyp. Although this entity is not commonly seen in daily clinical practice, careful assessment is needed to not miss the diagnosis for early treatment to avoid unwanted complications.

Keywords: Giant antrochoanal polyp; Child; Adenoids; Differential diagnosis; Case report.

DOI: [10.33091/amj.2022.176312](https://doi.org/10.33091/amj.2022.176312)

© 2022, Al-Anbar Medical Journal



INTRODUCTION

Antrochoanal or Killian's polyps are benign, non-atopic masses that arise from the maxillary antrum, through their natural or accessory Ostia and passes through the nose to the choana and may reach the nasopharynx [1]. The majority of these polyps are small in size with a silent clinical course and are usually detected as incidental lesions [2]. However, giant antrochoanal polyp is rarely seen in the daily Otolaryngology practice. Antrochoanal polyp comprises 4-6% of nasal polyps in adulthood and 28% in the pediatric population, with an incidence rate of 1 to 2 per 10000 [3]. Despite antrochoanal polyps being usually unilateral, bilateral polyps have also been reported in the literature [4]. Unilateral nasal obstruction and rhinorrhea are the commonest presenting symptoms. We presented a case of large left antrochoanal polyp in a 6-years-old boy who presented with respiratory and swallowing abnormalities.

CASE PRESENTATION

A 6-years-old boy presented to the Otolaryngology clinic with bilateral nasal obstruction, nasal and post-nasal mucopurulent discharge, mouth breathing, hypo-nasal speech, snoring, and obstructive sleep apnea syndrome for a one-year duration. The condition was not resolved with many courses of antibiotics plus local decongestants. The patient's general condition was normal before starting his problem. There was no history of allergic rhinitis or any atopic diseases. The history was highly suggestive of adenoid hypertrophy as the cause of the child's symptoms. Rigid endoscopic evaluation of the nose revealed a pale glistening mass in the left nasal cavity arising from the middle meatus and extending through the nose to the nasopharynx. Oropharyngeal examination revealed a swelling extending from the nasopharynx downward to the oropharynx pushing the soft palate forward and upward as shown in Figure 1.

Computerized tomography (CT) scan showed a hypo-attenuated mass completely occupying the left maxillary sinus, extending to the nose and reaching the oropharynx through the nasopharynx (red Astrix in Figures 2 A and B).

Antrochoanal polyp was diagnosed. Under general anesthesia with orotracheal intubation, the oropharyngeal portion of the polyp was grasped and removed through the mouth by

*Corresponding author: E-mail: med.raed.alani2003@uoanbar.edu.iq
Phone number: +9647906145364

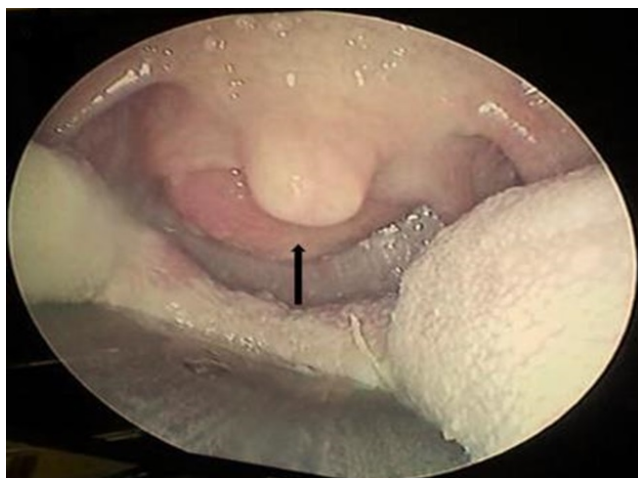


Figure 1. Endoscopic view of the oropharynx shows the polyp in the oropharynx pushing the uvula and soft palate forward and upward (black arrow).

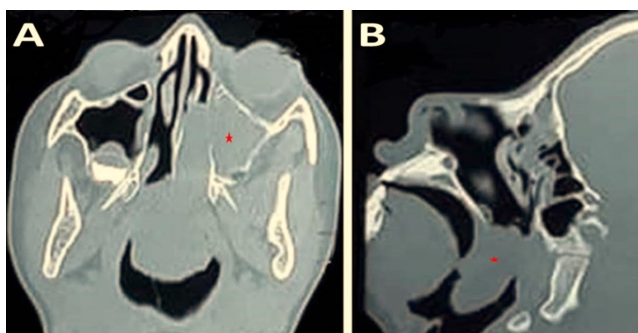


Figure 2. CT scan of the nose and paranasal sinuses. A: Axial view shows a hypo-attenuating lesion (red Asterix) occupying the left maxillary sinus and extending through the nose to the nasopharynx. B: Sagittal section revealed the hypo-attenuating lesion in the nasopharynx and oropharynx (red Asterix).

gentle traction under nasal endoscopic guidance as shown in Figure 3. While the antral portion of the polyp (attached to the posterior wall of the maxillary sinus) was removed through middle meatus antrostomy using the shaver and angled endoscope. The left nasal cavity was packed with a Merocele pack. The excised specimens were sent for histopathological evaluation. The histopathological examination confirmed the diagnosis of the antrochoanal polyp (Figure 4). The pack was removed 24 hours following surgery. The condition was resolved following the excision of the polyp. The postoperative course passed smoothly without complications. At a 2 year follow-up, the child remained free of the presenting symptoms. Informed consent was taken from the patient's father to publish the presenting case in a scientific journal.

DISCUSSION

The mechanisms and causes of antrochoanal polyps are still not understood, however, cystic fibrosis and chronic rhinosinusitis might be implicated [5]. Despite that, polyps due to allergy (abundant eosinophils) were detected more than in-

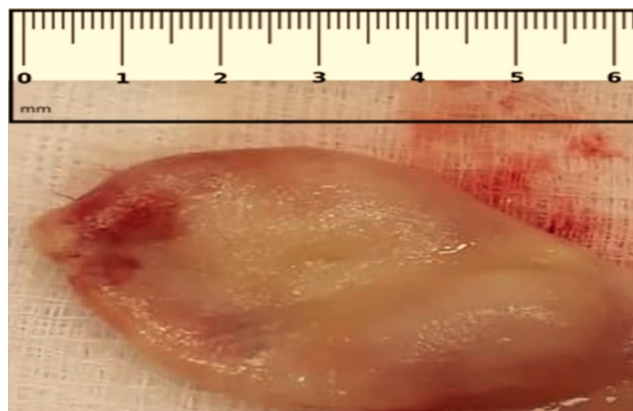


Figure 3. The excised choanal portion of the giant antrochoanal polyp.

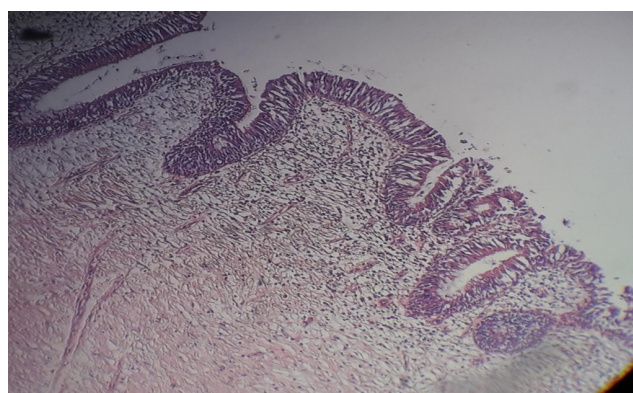


Figure 4. Polypoid lesion lined by respiratory epithelium overlying a highly vascular myxoid stroma (Hematoxylin and Eosin \times 100).

flammatory polyps (abundant neutrophils) in the pediatric population by histopathological examination [6]. Moreover, Chen et al. revealed that 50% of the patients had a history of allergic diseases in children with antrochoanal polyps [3].

It is well known that antrochoanal polyps occur mainly in the pediatric and young adult population [1, 7, 8]. However, a study by Lee et al. showed that about 40% of their patients were 30-65 years [9]. Moreover, the prior study reported that antrochoanal polyps are presented at any age [6]. Therefore, antrochoanal polyps may occur at any age.

Antrochoanal polyps in the pediatric population are usually presented at an advanced stage due to delayed diagnosis [9]. In the presenting case, there was a long elapsing time between the child's symptoms and the diagnosis because it was misdiagnosed as a case of adenoid hypertrophy. If the giant antrochoanal polyp is associated with adenoids, the polyp can extend to another nasal cavity because the adenoids act as a barrier preventing the polyp from its natural pathway [10].

The usual presentation of the antrochoanal polyps is unilateral nasal obstruction and rhinorrhea. Other symptoms might be found in certain patients, such as epistaxis, smell hypo-function, and headache. However, bilateral nasal obstruction, mouth breathing, rhinorrhea, nasal speech, snoring, and obstructive sleep apnea syndrome are the features of bi-

lateral and giant unilateral antrochoanal polyps. Besides, the difficulty in swallowing and plummy voice are cardinal symptoms of the giant polyp as found in the current case.

In reviewing the literature, several cases of the giant antrochoanal polyps were reported at different ages [11–19]. Besides, Spadijer-Mirkovi et al. [20] reported two patients with giant antrochoanal polyps, one of them was a 15-year-old boy and the other was a 38-year-old male. The age of the presenting case was the youngest age of the previously reported cases of giant antrochoanal polyps. It is an interesting finding in these 12 reported cases (11 previous reported cases plus the presenting case) that 10 cases were males and two cases were females [12, 17]. This leads us to hypothesize that giant antrochoanal polyps occur mainly in males.

The gold standard techniques for the diagnosis of antrochoanal polyps are endoscopic nasal examination and CT scan evaluation of the nose and paranasal sinuses. According to the CT features, the antrochoanal polyps are classified into 3 stages [21]: stage 1 (the polyp extends to the nose), stage 2 (the polyp extends to the nasopharynx and the maxillary ostium is occluded fully by the polyp neck), and stage 3 (similar to stage 2 but the maxillary ostium is partially occluded by polyp neck). The presenting case was in stage 3. Besides, it extends to the oropharynx resulting in severe respiratory and swallowing disorders. Lee et al. reported that CT stage 2 and 3 antrochoanal polyps were more common than stage 1 in children in comparison with adults (P-value < 0.001) [9]. Late diagnosis of the antrochoanal polyps in children as in our case is the reason for advanced CT stages [9].

The differential diagnosis of large antrochoanal polyp includes benign (adenoids, juvenile angiofibroma, teratoma, meningoencephalocele, chordoma, paraganglioma, and nasopharyngeal extension of a para-pharyngeal parotid tumor) and malignant diseases (carcinoma, lymphoma, and sarcoma) [12].

The main objective of the antrochoanal polyp treatment is complete excision of the polyp with a complete cleaning of the involved maxillary antrum [13]. The endoscopic nasal approach and/or trans-canine approach is capable to achieve this aim. The choice of the approach depends on the attachment of the polyp to the maxillary antral walls. If the polyp arises from the lateral wall of the maxillary sinus, combined approaches are indicated because they give adequate access to remove the polyp in toto [8]. While the endoscopic approach is enough to remove the polyp fully if the polyps arise from the other walls. Of note, the recurrence rate of antrochoanal polyp through an endoscopic approach varies between 0-36% according to several studies [22]. The giant

antrochoanal polyp of the presenting case was removed completely from its posterior wall attachment of the left maxillary sinus using the endoscopic approach. There were no postoperative complications. There was no recurrence of the polyp at the two-year follow-up.

CONCLUSION

We reported a further case of giant antrochoanal polyp in a young boy. Antrochoanal polyp should be kept in mind in the differential diagnosis of children with unilateral or bilateral nasal obstruction to avoid delay in the diagnosis and treatment. Complete excision can be achieved with an endoscopic approach.

ETHICAL DECLARATIONS

Acknowledgements

None.

Ethics Approval and Consent to Participate

This study was approved by the Ethical Approval Committee of the University Of Anbar. Written informed consent was obtained from the patients' father for the publication of this case report and accompanying images.

Consent for Publication

The patients' father gave written informed consent for the publication of the data and materials contained within this study.

Availability of Data and Material

All data related to the presenting case were present in this article.

Competing Interests

The author declares that there is no conflict of interest.

Funding

No funding.

Authors' Contributions

Al-Ani RM analyzed and interpreted the patient data regarding the clinical, radiological, and pathological finding as well as writing the case presentation. Al-Ani RM was responsible for writing the whole manuscript. Al-Ani RM read and approved the final manuscript draft.

REFERENCES

- [1] A A El-Sharkawy. Endoscopic management of paediatric antrochoanal polyp: our experience. *Acta Otorhinolaryngologica Italica*, 33(2):107, 2013.
- [2] Neha Keshri, Avi Bansal, Gourav Popli, Arvind Venkatesh, and Siddhartha Goel. Antrochoanal polyp arising from benign pseudocyst of maxillary antrum. *Journal of Indian Society of Pedodontics and Preventive Dentistry*, 35(3):275, 2017.
- [3] J M Chen, M D Schloss, and M E Azouz. Antro-choanal polyp: a 10-year retrospective study in the pediatric population with a review of the literature. *The Journal of otolaryngology*, 18(4):168–172, 1989.
- [4] Suha Ertugrul. Origin of polyps and accompanying sinonasal pathologies in patients with antrochoanal polyp: Analysis of 22 patients. *Northern clinics of Istanbul*, 6(2):166, 2019.

- [5] H M Myatt and M Cabrera. Bilateral antrochoanal polyps in a child: a case report. *The Journal of Laryngology & Otology*, 110(3):272–274, 1996.
- [6] P Frosini, G Picarella, and E De Campora. Antrochoanal polyp: analysis of 200 cases. *Acta Otorhinolaryngologica Italica*, 29(1):21, 2009.
- [7] S. Aydn *et al.* The analysis of the maxillary sinus volumes and the nasal septal deviation in patients with antrochoanal polyps. *European Archives of Oto-Rhino-Laryngology*, 272(11):3347–3352, 2015.
- [8] Ta-Jen Lee and Shiang-Fu Huang. Endoscopic sinus surgery for antrochoanal polyps in children. *Otolaryngology Head and Neck Surgery*, 135(5):688–692, 2006.
- [9] Dong Hoon Lee, Tae Mi Yoon, Joon Kyoo Lee, and Sang Chul Lim. Difference of antrochoanal polyp between children and adults. *International Journal of Pediatric Otorhinolaryngology*, 84:143–146, 2016.
- [10] Eiji Yanagisawa, John K Joe, and Joe A Pastrano. Unilateral antrochoanal polyp with bilateral nasal obstruction. *Ear, Nose & Throat Journal*, 77(3):170, 1998.
- [11] Eiji Yanagisawa, Stephen J Salzer, and Ronald H Hirokawa. Endoscopic view of antrochoanal polyp appearing as a large oropharyngeal mass. *Ear, Nose & Throat Journal*, 73(10):714–715, 1994.
- [12] Eaton Chen and Eiji Yanagisawa. An unusually large choanal polyp that almost completely obstructed the oropharyngeal airway. *Ear, Nose & Throat Journal*, 85(8):474–476, 2006.
- [13] Leyla Kansu and Erdinç Aydin. Atypical presentation of antrochoanal polyp in a child. *Turk J Pediatr*, 53(3):320–324, 2011.
- [14] E A Cetinkaya. Giant antrochoanal polyp in an elderly patient: case report. *ACTA Otorhinolaryngologica Italica*, 28(3):147, 2008.
- [15] Jih-Chin Lee and Ying-Liang Chou. Antrochoanal Polyp. *New England Journal of Medicine*, 362(22):2113, 2010.
- [16] Afshin Teymoortash. Intraoral presentation of antrochoanal polyp. *N Eng J Med*, 371:766, 2014.
- [17] Karol V Čanji and Slobodan M Mitrović. Giant antrochoanal polyp: Case report and literature review. *Medicinski prehled*, 67(11-12):410–412, 2014.
- [18] Yoko Hori, Kana Taniguchi, Tadashi Okabe, and Atsuhiko Sakamoto. A case of unexpectedly difficult intubation caused by a large asymptomatic choanal polyp. *JA clinical reports*, 2(1):2, 2016.
- [19] Swati Kodur, Shruti Malavalli Siddappa, and Andanooru Mahalingappa Shivakumar. Giant Antrochoanal Polyp-A Rare Presentation. *Journal of clinical and diagnostic research: JCDR*, 11(1):MD01, 2017.
- [20] Cveta Spadijer-Mirković, Aleksandar Perić, Biserka Vukomanović-urević, and Ivan Stanojević. Clinical case report of a large antrochoanal polyp. *Acta Medica (Hradec Kralove)*, 57(2):78, 2014.
- [21] Seung-Kyu Chung, Byung-Chan Chang, and Hun-Jong Dhong. Surgical, radiologic, and histologic findings of the antrochoanal polyp. *American journal of rhinology*, 16(2):71–76, 2002.
- [22] Yassir Hammouda, Omar Berrada, Sami Rouadi, Redallah Larbi Abada, and Mohamed Mahtar. Treatment and evaluation of recurrence for antrochoanal polyps by endoscopic large middle meatal antrostomy, clinical case series of 25 patients. *International Journal of Surgery Case Reports*, 77:651–655, 2020.