

The Potential of Omega–3 Fatty Acids in the Treatment of Dry Eye Disease: A Narrative Review

Nejra Hodžić,¹ Ines Banjari,^{2,*} Priyadarshini Bhoi,¹ Zumra Hodžić,³ Zlatko Mušanović,⁴ and Amra Nadarević-Vodenčarević⁴

¹Department of Ophthalmology, Plava Medical Group,
3. Tuzlanske brigade 7, 75000 Tuzla, Bosnia & Herzegovina.

²Department of Food and Nutrition Research, Faculty of Food Technology Osijek, F. Kuhača 18, 31000 Osijek, Croatia.

³Department of Family Medicine, Health Care Center,
Kulina bana bb, 75300 Lukavac, Bosnia & Herzegovina.

⁴Department of Ophthalmology, University Clinical Center,
Trnovac bb, 75000 Tuzla, Bosnia & Herzegovina.

(Received : 22 November 2023; Accepted : 1 March 2024; First published online: 21 March 2024)

ABSTRACT

As one of the most common diseases in ophthalmology today, dry eye disease (DED) poses a great challenge for public health systems globally. This is a multifactorial condition involving the production/evaporation of tears and consequential damage to the ocular surface. Symptoms of DED like discomfort and visual disturbance alter a person's quality of life and pose a significant economic burden to healthcare systems. Today's lifestyle favors DED development, especially long-term exposure to screens, poor sleep quality, and a diet abundant in saturated fats and omega-6 fatty acids, and we can expect that its prevalence will extend far beyond the currently estimated 10%. The underlying inflammation and symptoms of DED, are treated with various anti-inflammatory agents and autologous and/or allogeneic serum drops. Considering the role of lifestyle in DED pathophysiology, lifestyle modifications, including diet, sleep, and physical activity are getting more attention. Among them, supplementation with omega-3 fatty acids shows the most promising results in alleviating subjective and objective measures of DED through a direct effect on the stability and production of the tear film, inflammation markers, and corneal nerve regeneration. We aimed to provide insights into currently available research findings supporting omega-3 fatty acids as a valuable adjuvant therapy in treating DED.

Keywords: Dry Eye Disease; Tear; Omega–3 Fatty Acids; Supplementation; Diet.

DOI: [10.33091/amj.2024.144837.1450](https://doi.org/10.33091/amj.2024.144837.1450)

© 2024, Al-Anbar Medical Journal



INTRODUCTION

As one of the most common diagnoses in ophthalmology, dry eye disease (DED) affects 10–30% of the global population [1, 2]. It affects 10% of adults aged 30–60 year and 15% of adults over 65 year [3]. The economic burden of DED is substantial; based on the systematic review of literature from 2016 [4], direct costs vary greatly between Europe, the United States, and Asia, but in all three regions, the largest share of the overall

economic burden goes to indirect costs due to sick-leaves and reduced productivity. Costs are higher for female patients [5] and for more severe forms of the disease [6, 7].

Women are generally more susceptible to DED, especially if on estrogen replacement therapy. Also, DED prevalence is higher among people with blepharitis, Meibomian gland dysfunction, and change of the conjunctiva, as well as in people suffering from various systemic chronic conditions like cardiovascular diseases, thyroid diseases, arthritis, and osteoporosis, and among people who have had a corneal, retinal, or oncological eye surgery [8–10].

DED can cause serious life-quality impairment affecting many daily activities, from driving, and reading, to the ability to spend time in front of a screen (computer, television)

* Corresponding author: E-mail: ibanjari@ptfos.hr
This is an open-access article under the CC BY 4.0 license

[11]. Today's lifestyle represents ideal environment for DED. Long-term use of computers and exposure to various screens, insufficient sleep, psychological stress [12], a Westernized diet abundant with omega-6 fatty acids [11] and metabolic diseases that promote oxidative stress and inflammation [13], are proven underlying risk factors in the pathology of DED [14]. As proposed by Kojima *et al.* [13], DED can be observed as a lifestyle disease. In that sense, promoting lifestyle changes focused on diet, sleep, and exercise could possibly prevent the onset and reduce the economic and societal burden of DED.

Recent evidence suggests that topical application and oral supplementation with omega-3 fatty acids could be effective adjuvant therapies in the treatment of DED [15]. Even though we don't fully understand how it works, most randomized controlled studies [16] have found that the anti-inflammatory properties of omega-3 fatty acids are the main reason why both subjective and objective measures of DED get better. This review provides an overview of currently available research findings regarding the potential of omega-3 fatty acids in the treatment of DED.

PATHOPHYSIOLOGY OF DRY EYE DISEASE

Dry eye is a multifactorial disease of the production and evaporation of tears due to decreased function of the lacrimal glands and consequent dryness of the conjunctiva and cornea [17, 18]. It is manifested as discomfort, visual disturbances, and instability of the tear film, with the possibility of leading to significant damage to the ocular surface [17].

The clinical term "dry" eye is increasingly being abandoned, given that the etiology of the disorders implied by the term extends far beyond the lack of tears, putting the emphasizing the dysfunction of the tear film as the main cause of the disease [8].

Triggers in the pathophysiology of DED are various stress factors on the ocular surface, from environmental factors, infections, endogenous stress, and antigens, to genetic factors. Ageing, female gender, some medications (like antidiabetics, antihypertensives, antidepressants, thyroid drugs, antihistamines, antiepileptics, antipsychotics, antiparkinsonian drugs, antiglaucoma drugs, and oral contraceptives), and conditions (such as refractive surgeries, irregular blinking, and long-term use of contact lenses) promote DED [17–19]. Damage to the ocular surface is a result of activation of the autoreactive T helper cells, which infiltrate the ocular surface and lacrimal gland, as a result of pro-inflammatory cytokine and chemokine production, and the activation of matrix metalloproteinases [18, 20]. Finally, osmolarity of the tear film and inflammation of the ocular surface increase [17, 21, 22]. A higher level of depression or anxiety has also been consistently reported in patients with clinical diagnosis of DED and those with self-reported DED [23].

The tear film is approximately $3\mu\text{m}$ thick, and its composition is in a very dynamic flux, whose specific content varies depending on the environment and body conditions [19, 24]. Three main layers of the tear film are shown in Figure 1:

1. The surface, or lipid layer, of the tear film - serves to reduce the evaporation of the aqueous layer when the eye is open. It is primarily secreted by the Meibomian glands (modified sebaceous glands) in the edges of the eyelids and, in smaller amount, by the Moll (modified apocrine, sudoriferous) and Zeiss (modified sebaceous) glands, located within the superior and lower eyelids [25].
2. The central, aqueous layer that lubricates the eye surface also contains numerous electrolytes, proteins, growth

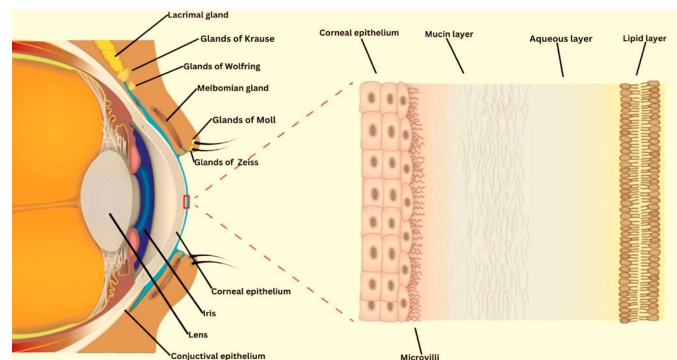


Figure 1. Tear film layers and their sources of production (Source: [19]. All right to the Int. J. Mol. Sci.).

factors, vitamins, antimicrobial agents, cytokines, immunoglobulins, and hormones. It makes up 90% of the volume of the tear film [24], and its main purpose is to nourish and protect the ocular surface. It is secreted by the main lacrimal glands and the Krause and Wolfring glands (accessory lacrimal glands) located in the conjunctiva of the superior eyelid and superior conjunctival fornix [25].

3. The inner, mucinous layer that has function of moisturizing and covering the cornea. It is produced by conjunctival and corneal epithelium, the lacrimal gland, and conjunctival goblet cells [25].

Patients reported a variety of symptoms, including irritability, scratching, burning, foreign body sensations, and blurred vision [26]. However, these often overlap with other ocular surface pathologies, leading to a delayed diagnosis [27]. In 43% of patients with DED, a longer time to diagnosis (more than one year) negatively affects the quality of life [23, 26]. Advanced conditions can result in damage to the front surface of the eye, presented as a serious change in visual acuity [8], which deepens the negative effect on work productivity and overall quality of life [23, 26].

CLASSIFICATION OF DRY EYE DISEASE

There are two types: 1) dry eye due to the so-called tear deficit, or hyposecretory dry eye; and 2) dry eye due to excessive evaporation of tears, the so-called evaporative dry eye or hyperevaporative dry eye given that it appears under normal conditions [28].

More than 80% of patients have either a hyperevaporative disorder, mainly caused by the Meibomian gland dysfunction, or a mixed hyperevaporative or hyposecretory form of DED, while around 10% have a hyposecretory form of DED [17]. Hyposecretory dry eye includes Sjögren's syndrome, non-Sjögren's tear deficiency, and evaporative or hyperevaporative dry eye, but patients can simultaneously have both conditions [8].

The most common form is age-related dry eye [29]. Between blinks, the aqueous layer of the tear film evaporates to some extent in all people, regardless of whether they suffer from DED or not. This results in a change in the tone of the tear film (osmolarity), which furthermore accounts for areas on the surface of the eye where the tear film has disappeared. Blinking the eyelid replenishes the outer lipid layer covering the aqueous layer, relubricates, and redistributes the lipid layer across the ocular surface [28]. Therefore, an intact

outer lipid layer will ensure proper maintenance (and expansion) of the aqueous layer.

Evaporative dry eye may be a consequence of the lack of lipids produced by the Meibomian glands, poor compliance and dynamics of the eyelids, low blink frequency, and the effects of some medications (antidiabetics, antihypertensives, antidepressants, thyroid drugs, and antihistamines) [8].

DIAGNOSIS OF DRY EYE DISEASE

Symptoms of dry eye are commonly perceived as the main feature of the disease. However, except in severe cases, the results of diagnostic tests are completely the opposite, probably because the diagnosis is based on a combination of subjective and objective tests. Subjective symptoms are tested with questionnaires, and the most commonly used are the Ocular Surface Diseases Index (OSDI questionnaire), Dry Eye Questionnaire (DEQ questionnaire), National Eye Institute Visual Function Questionnaire (NEIVFQ-25 questionnaire), Ocular Comfort Index (OCI questionnaire), Symptom Assessment in Dry Eye (SANDE questionnaire), Impact of Dry Eye in Everyday Life (IDEEL questionnaire), etc. [17, 30, 31].

The most commonly objective methods used in the diagnosis of dry eye diagnosis are Schirmer's test and the Tear Break-up Time Test (TBUT) [13, 17]. Schirmer's test provides an insight into the quantity of tears, while TBUT tests the stability of the precorneal tear film, i.e. the quality of tears. There are other useful objective tests, such as conjunctival (for the evaluation of goblet cells) and brush cytology (for the evaluation of ocular surface inflammation), and measurement of lysozyme and lactoferrin levels in tears [32].

THERAPEUTIC APPROACHES TO DRY EYE DISEASE

A wide range of treatment options for DED are available, all aiming to alleviate the symptoms experienced by patients, improve visual acuity, and finally, improve patients' quality of life. The first line of treatment relies on the application of artificial tears. They improve the symptoms experienced by patients and can also alleviate ocular surface inflammation [2]. They do not have a direct anti-inflammatory effect [33], but they dilute pro-inflammatory cytokines on the ocular surface and reduce the osmolarity of the tear [2].

Symptoms of DED can be treated with anti-inflammatory agents, topically and/or systemically, such as corticosteroids, cyclosporine A, and doxycycline [21]. Based on the recent Cochrane meta-analysis of 34 randomized controlled trials involving 4314 adults diagnosed with DED of variable severity and etiology from 13 countries [34], omega-3 fatty acids supplementation in comparison to placebo/control supplementation showed promising results on DED symptoms.

For milder cases of DED, it is sufficient for a person to avoid long exposure to screens or reading, which reduce blink rate and promote evaporation of the aqueous layer of the tear film. If prolonged screen time is impossible to avoid, short breaks during these activities, and the use of artificial tears are recommended to alleviate the symptoms. For more severe cases, artificial tears without preservatives are required in combination with anti-inflammatory agents or tetracyclines (for inflammation and swelling of the Meibomian glands or rosacea). Also, punctal plugs can be applied after the inflammation has subsided, glasses with a moisture retention chamber, the application of autologous serum, contact lenses

can be prescribed or even permanent punctal occlusion and surgery [31, 33].

OMEGA-3 FATTY ACIDS

The integrity and function of all cell membranes depend on polyunsaturated fatty acids (PUFAs), which are a key player in many chronic conditions of today's society, from cardiovascular diseases to cancer [35, 36], cognition [37], and neurodegeneration [38].

Omega-3 and omega-6 fatty acids are derived from two essential fatty acids: 1) α -linolenic acid (ALA), which is a precursor to eicosapentaenoic acid (EPA), then further metabolized to docosahexaenoic acid (DHA), members of the omega-3 family; and 2) linoleic acid (LA), along with arachidonic acid (ARA), members of the omega-6 family [35]. Beneficial health effects are attributed to omega-3 PUFAs, i.e. EPA and DHA [35, 39], but also to their derivatives, such as resolvins and neuroprostanes [40, 41].

Since omega-3 and omega-6 fatty acids cannot be produced in the body, diet and/or supplements represent their only source. Table 1 shows their most important dietary sources. ALA is concentrated in many plant-based foods, while EPA and DHA are highly abundant in marine (aquatic) sources [42–44].

Globally, fish consumption is low, which results in a diet low in omega-3 fatty acids in all population groups [45–48]. An effective strategy proposed to improve EPA and DHA status is the use of supplements containing omega-3 fatty acids [42]. Depending on the outcome measure [37, 49, 50], doses of omega-3 fatty acids supplements used across studies are most commonly 2 or 3 g per day, but caution is needed with higher doses where more adverse effects can be expected, including diarrhea, dysgeusia, and bleeding tendency [51].

In terms of eye health, omega-3 and omega-6 fatty acids are important in maintaining the homeostasis of the ocular surface [16]. They were found to be effective in modulating the inflammation in DED through improved composition of the lipid layer of the tear film and promotion of the corneal nerve regeneration [31]. *In vitro*, resolvin D1 reduces the synthesis of inflammatory cytokines in the corneal epithelium [52]. Another *in vitro* study found that resolvin D1 inhibited pro-inflammatory cytokines production, including interferon

Table 1. Food sources of omega-3 fatty acids (prepared by the authors based on the references [39–41])*.

Food sources of ALA	Food sources of EPA and DHA
Plant oils, especially flaxseed oil, soy, walnut, pumpkin	Herring
Seeds, especially flax, chia, hemp	Salmon
Canola oil	Sardines
Seaweed	Mackerel
Nuts, especially walnuts	Trout
Soybean	Cod
Spinach	Oysters, shrimps, scallops
Broccoli	Sea bass
Beans	Tuna

* ALA–Alpha-Linolenic Acid; EPA–Eicosapentaenoic Acid; DHA–Docosahexaenoic Acid

(IFN)- γ , IL (interleukin)-6, and tumor necrosis factor (TNF)- α , and decreased cyclooxygenase-2 gene expression after human Meibomian gland epithelial cells were supplemented with EPA and DHA [53].

SYSTEMIC EFFECTS OF OMEGA-3 FATTY ACIDS IN DRY EYE DISEASE

The number of registered randomized clinical trials about the effect of omega-3 fatty acids in DED (according to the search conducted in January 2024 in the ClinicalTrials.org registry) is 34. The majority of randomized clinical trials that are analyzed in available systematic reviews and/or meta-analysis support the efficacy of omega-3 fatty acid supplementation on the symptoms and progression of DED [34, 54, 55]. A more recent systematic-review and meta-analysis from 2023, found objective improvement in OSDI but not in other objective measures of DED like Schirmer's test. TBUT, or corneal staining, after analyzing eight randomized clinical trials including 1107 patients, concluded that no evident improvement was achieved in terms of DED after omega-3 fatty acid supplementation [56].

Walter *et al.* [57] found an increase in the omega-6/omega-3 ratio in tear lipids, which was proportional to corneal staining and the degree of the tear film dysfunction, suggesting that omega-3 fatty acid deficiency in the tear film may act as a promoting factor for the inflammation of the ocular surface. Another mechanism through which omega-3 fatty acids act protectively in DED is through their incorporation into the lacrimal gland [58]. Concentrations of EPA and DHA in the lacrimal glands increased after mice were supplemented with EPA and DHA, increasing the height of the lacrimal meniscus [59].

In a large population-based study, involving 32,470 women, the risk of developing DED was more than doubled with a higher ratio of omega-6/omega-3 intake ($> 15:1$ *vs.* $< 4:1$) [11]. In the same study, the incidence of DED was 68% lower in women with a higher intake of omega-3 fatty acids [11].

More interest is put on the role of neurosensory dysfunction in the etiology of DED [60], given that patients with DED have changes in the corneal sensation and a reduced number and density of the sub-basal corneal nerve plexus. Oral supplementation with omega-3 fatty acids (combination of 1000 mg EPA and 500 mg DHA for 3 months) provided a neuroprotective effect in the corneal sub-basal plexus, which correlated significantly with the extent of normalization in the tear film osmolarity [61].

The study by Wojtowicz *et al.* [62] found that taking fish oil (450 mg EPA and 300 mg DHA) every day for 90 days increased the amount and quantity of tears that were produced without having a noticeable effect on the lipid makeup of the Meibomian glands in the tarsus or the rate at which the watery part of tears evaporated. Short-term supplementation with 360 mg EPA and 240 mg DHA per day for 30 days improved symptoms of DED, including tear volume and stability [63]. For three months, taking the same amount of omega-3 fatty acids (360 mg EPA and 240 mg DHA per day) as a supplement eased DED symptoms, especially those linked to computer vision syndrome. It also slowed down the rate at which tears evaporated and improved the conjunctival epithelium as seen by impression cytology [64]. TBUT scores, along with DED symptoms, were improved after supplementation with fish oil containing 1245 mg EPA and 540 mg DHA per day for 12 weeks [65]. Another randomized clinical trial in

rosacea patients found that a 6 month supplementation with omega-3 fatty acids significantly improved DED symptoms, TBUT, Schirmer's test, and the Meibomian gland score [66]. People with blepharitis and Meibomian gland disease (MGD) who take flaxseed oil as a supplement (6000 mg/day, made up of 55% ALA and 15% LA) have higher levels of omega-3 fatty acids in their blood, lower levels of omega-6 to omega-3 in their plasma, and better DED, TBUT, and Meibomian gland test results [67]. Another randomized controlled trial on 50 DED with MGD patients randomized to either placebo (olive oil) or 600 mg EPA and 1640 mg DHA per day for 8 weeks found significant improvements in TBUT and MGD scores, suggesting stabilization of the tear film [68].

However, the results of a multicenter double-blind randomized clinical trial, DREAM, involving 349 DED patients receiving 2000 mg EPA and 1000 mg DHA per day, and 186 patients with DED receiving a placebo (olive oil) during 12 months did not find significant improvement in any of the observed outcomes between the two groups [69].

TOPICAL EFFECTS OF OMEGA-3 FATTY ACIDS IN DRY EYE DISEASE

The innervation of the cornea is sensory, and any interruption can affect the morphology and function of the epithelium, poor tear film production, and delayed wound healing.

The lacrimal gland secretion is controlled by the neural reflex arc of sensory afferent nerves (trigeminal sensory fibers) of the cornea and conjunctiva. In this connection, damage to the sensory nerves of the cornea impairs the function of the lacrimal gland and can cause dry eye syndrome [70]. Damage to the innervation of the cornea occurs during refractive eye surgeries (PRK and LASIK are the most common procedures today). As many as 60% of people after the LASIK procedure have dry eye syndrome one month after surgery, and symptoms of irritation and dryness are felt by 50% of people 6 months after surgery [71]. One prospective study has found an 80% nerve density recovery within 2 years after PRK, remaining stable at 5-year follow-up [72]. These results suggest that for the recovery of the normal corneal surface, proper regrowth of corneal nerves in the area of corneal ablation is essential. This can be achieved through the topical application of nerve growth factor (NGF), responsible for the survival, growth, and differentiation of sensory neurons [73]. Researchers found that it worked better when mixed with DHA; more epithelial cell proliferation was seen in the basal corneal epithelium when NGF was used alone [70]. The possible mechanism of action is through the activity of neuroprotectin D1 (NPD1), the DHA-derived lipid mediator, which poses anti-inflammatory and neuroprotective effects [70]. Additionally, local application of resolvin E1 [74] and neuroprotectin D1 in combination with NGF [70] was also found to alleviate inflammation in DED.

CONCLUSION

Low consumption of omega-3 fatty acids through diet results in a higher omega-6/omega-3 ratio, which reflects negatively on the integrity and function of all cell membranes, including the eye. Fast-paced lifestyles leading to shorter sleep, prolonged period of time using a mobile or computer, and sedentary lifestyles contribute to the development of DED. However, due to its multifactorial presentation and symptoms that often overlap with other ophthalmological condi-

tions, DED can remain undiagnosed for a prolonged time. The negative impact, not only on a personal level but also on society, has been well documented. The diagnosis relies on both subjective and objective measures, and treatment options currently available range from artificial tears, and anti-inflammatory agents to other methods, including surgery. More recently, several randomized clinical trials have found that omega-3 fatty acids are an effective adjuvant therapy. Supplementation with omega-3 fatty acids (a combination of EPA and DHA) improved tear production, reduced tear evaporation, reduced inflammation markers, corneal nerve regeneration, and improved subjective symptoms of DED. Despite variable doses and intervention duration, studies confirmed omega-3 fatty acids to be safe and well tolerated. More studies are needed, especially prospective studies and those that would analyze the combined effect of omega-3 fatty acids from diet and supplements on DED incidence.

ETHICAL DECLARATIONS

Acknowledgements

None.

Ethics Approval and Consent to Participate

Not required.

Consent for Publication

None.

Availability of Data and Material

None.

Competing Interests

The authors declare that there is no conflict of interest.

Funding

No funding.

Authors' Contributions

N.H. collected literature data and drafted the first manuscript, made corrections according to inputs from co-authors. N.H., Z.H., A.NV., and Z.M. edited the manuscript. I.B. suggested the topic, supervised N.H., reviewed the manuscript. IB conducted all correspondence with the Editorial Board. All authors read and approved the final manuscript.

REFERENCES

- [1] S. B. Han, J. Y. Hyon, S. J. Woo, J. J. Lee, T. H. Kim, and K. W. Kim. Prevalence of dry eye disease in an elderly Korean population. *Archives of ophthalmology*, 129(5):633–638, 2011.
- [2] C. Baudouin *et al.* Clinical impact of inflammation in dry eye disease: proceedings of the ODISSEY group meeting. *Acta ophthalmologica*, 96(2):111–119, 2018.
- [3] C. Yazdani, T. McLaughlin, J. E. Smeeding, and J. Walt. Prevalence of treated dry eye disease in a managed care population. *Clinical therapeutics*, 23(10):1672–1682, 2001.
- [4] M. McDonald, D. A. Patel, M. S. Keith, and S. J. Snedecor. Economic and humanistic burden of dry eye disease in Europe, North America, and Asia: a systematic literature review. *The ocular surface*, 14(2):144–167, 2016.
- [5] Y. Luo *et al.* Annual Direct Economic Burden and Influencing Factors of Dry Eye Diseases in Central China. *Ophthalmic Epidemiology*, 30(2):121–128, 2023.
- [6] C. Chan, S. Ziai, V. Myageri, J. G. Burns, and C. L. Prokopich. Economic burden and loss of quality of life from dry eye disease in Canada. *BMJ Open Ophthalmology*, 6(1):e000709, 2021.
- [7] W. Yang *et al.* Estimated annual economic burden of dry eye disease based on a multi-center analysis in China: a retrospective study. *Frontiers in Medicine*, 8:771352, 2021.
- [8] I. Bakija. Kvaliteta suznog filma u kroničnih shizofrenih bolesnika na dugotrajnoj terapiji antipsihoticima, 2021.
- [9] Z. A. I. Y. Hasan. Dry eye syndrome risk factors: A systemic review. *Saudi Journal of Ophthalmology*, 35(2):131, 2021.
- [10] F. E. Hakim and A. V. Farooq. Dry eye disease: An update in 2022. *Jama*, 327(5):478–479, 2022.
- [11] B. Miljanović, K. A. Trivedi, M. R. Dana, J. P. Gilbard, J. E. Buring, and D. A. Schaumberg. Relation between dietary n-3 and n-6 fatty acids and clinically diagnosed dry eye syndrome in women. *The American journal of clinical nutrition*, 82(4):887–893, 2005.
- [12] J. S. Wolffsohn *et al.* Demographic and lifestyle risk factors of dry eye disease subtypes: a cross-sectional study. *The Ocular Surface*, 21:58–63, 2021.
- [13] T. Kojima, M. Dogru, M. Kawashima, S. Nakamura, and K. Tsubota. Advances in the diagnosis and treatment of dry eye. *Progress in retinal and eye research*, 78:100842, 2020.
- [14] S. Nakamura *et al.* Involvement of oxidative stress on corneal epithelial alterations in a blink-suppressed dry eye. *Investigative Ophthalmology & Visual Science*, 48(4):1552–1558, 2007.
- [15] S. Barabino, J. Horwath-Winter, E. M. Messmer, M. Rolando, P. Aragona, and S. Kinoshita. The role of systemic and topical fatty acids for dry eye treatment. *Progress in retinal and eye research*, 61:23–34, 2017.
- [16] M. Pellegrini *et al.* The role of nutrition and nutritional supplements in ocular surface diseases. *Nutrients*, 12(4):952, 2020.
- [17] E. M. Messmer. The pathophysiology, diagnosis, and treatment of dry eye disease. *Deutsches Ärzteblatt International*, 112(5):71, 2015.
- [18] S. C. Pflugfelder and C. S. de Paiva. The pathophysiology of dry eye disease: what we know and future directions for research. *Ophthalmology*, 124(11):S4–S13, 2017.
- [19] M. Yazdani, K. B. P. Elgstøen, H. Rootwelt, A. Shahdadfar, Ø. A. Utheim, and T. P. Utheim. Tear metabolomics in dry eye disease: a review. *International Journal of Molecular Sciences*, 20(15):3755, 2019.
- [20] W. Stevenson, S. K. Chauhan, and R. Dana. Dry eye disease: an immune-mediated ocular surface disorder.

- Archives of ophthalmology*, 130(1):90–100, 2012.
- [21] H. Lam, L. Bleiden, C. S. De Paiva, W. Farley, M. E. Stern, and S. C. Pflugfelder. Tear cytokine profiles in dysfunctional tear syndrome. *American journal of ophthalmology*, 147(2):198–205, 2009.
- [22] F. Brignole-Baudouin *et al.* A multicentre, double-masked, randomized, controlled trial assessing the effect of oral supplementation of omega-3 and omega-6 fatty acids on a conjunctival inflammatory marker in dry eye patients. *Acta ophthalmologica*, 89(7):e591–e597, 2011.
- [23] K. G. Boboridis *et al.* Patient-reported burden and overall impact of dry eye disease across eight European countries: a cross-sectional web-based survey. *BMJ open*, 13(3):e067007, 2023.
- [24] M. E. Johnson and P. J. Murphy. Changes in the tear film and ocular surface from dry eye syndrome. *Progress in retinal and eye research*, 23(4):449–474, 2004.
- [25] D. Kopacz, L. Niezgoda, E. Fudalej, A. Nowak, and P. Maciejewicz. Tear film—physiology and disturbances in various diseases and disorders. *Ocular Surface Diseases—Some Current Date on Tear Film Problem and Keratoconic Diagnosis*, pages 137–144, 2020.
- [26] M. Labetoulle, M. Rolando, C. Baudouin, and G. van Setten. Patients' perception of DED and its relation with time to diagnosis and quality of life: an international and multilingual survey. *British Journal of Ophthalmology*, 101(8):1100–1105, 2017.
- [27] J. A. P. Gomes and R. M. Santo. The impact of dry eye disease treatment on patient satisfaction and quality of life: A review. *The ocular surface*, 17(1):9–19, 2019.
- [28] J. P. McCulley, W. E. Shine, J. Aronowicz, D. Oral, and J. Vargas. Presumed hyposecretory/hyperevaporative KCS: tear characteristics. *Transactions of the American Ophthalmological Society*, 101:141, 2003.
- [29] H. Nakamura, A. Kawakami, and K. Eguchi. Mechanisms of autoantibody production and the relationship between autoantibodies and the clinical manifestations in Sjögren's syndrome. *Translational Research*, 148(6):281–288, 2006.
- [30] Y. Okumura *et al.* A review of dry eye questionnaires: measuring patient-reported outcomes and health-related quality of life. *Diagnostics*, 10(8):559, 2020.
- [31] W. B. Jackson. Management of dysfunctional tear syndrome: a Canadian consensus. *Canadian Journal of Ophthalmology*, 44(4):385–394, 2009.
- [32] Y. Wu *et al.* Advances in dry eye disease examination techniques. *Frontiers in Medicine*, 8:826530, 2022.
- [33] D. Epidemiology. Subcommittee. The epidemiology of dry eye disease: Report of the epidemiology subcommittee of the international dry eye workshop (2007). *Ocul Surf*, 5(2):93–107, 2007.
- [34] L. E. Downie, S. M. Ng, K. B. Lindsley, and E. K. Akpek. Omega-3 and omega-6 polyunsaturated fatty acids for dry eye disease. *Cochrane Database of Systematic Reviews*, 12(12), 2019.
- [35] B. Kapoor, D. Kapoor, S. Gautam, R. Singh, and S. Bhardwaj. Dietary polyunsaturated fatty acids (PUFAs): Uses and potential health benefits. *Current Nutrition Reports*, 10:232–242, 2021.
- [36] Y. Wang *et al.* Does omega-3 PUFAs supplementation improve metabolic syndrome and related cardiovascular diseases? A systematic review and meta-analysis of randomized controlled trials. *Critical Reviews in Food Science and Nutrition*, pages 1–28, 2023.
- [37] I. M. Dighiri *et al.* Effects of omega-3 polyunsaturated fatty acids on brain functions: a systematic review. *Cureus*, 14(10), 2022.
- [38] R. Avallone, G. Vitale, and M. Bertolotti. Omega-3 fatty acids and neurodegenerative diseases: new evidence in clinical trials. *International journal of molecular sciences*, 20(17):4256, 2019.
- [39] F. Shahidi and P. Ambigaipalan. Omega-3 polyunsaturated fatty acids and their health benefits. *Annual review of food science and technology*, 9:345–381, 2018.
- [40] M. Arita *et al.* Resolvin E1, an endogenous lipid mediator derived from omega-3 eicosapentaenoic acid, protects against 2, 4, 6-trinitrobenzene sulfonic acid-induced colitis. *Proceedings of the National Academy of Sciences*, 102(21):7671–7676, 2005.
- [41] C. Cipollina. Endogenous generation and signaling actions of omega-3 fatty acid electrophilic derivatives. *BioMed research international*, 2015, 2015.
- [42] N. I. of Health. Omega-3 fatty acids—fact sheet for health professionals, 2019.
- [43] G. Rizzo, L. Baroni, and M. Lombardo. Promising sources of plant-derived polyunsaturated fatty acids: A narrative review. *International Journal of Environmental Research and Public Health*, 20(3):1683, 2023.
- [44] H. Duan, W. Song, J. Zhao, and W. Yan. Polyunsaturated Fatty Acids (PUFAs): Sources, Digestion, Absorption, Application and Their Potential Adjunctive Effects on Visual Fatigue. *Nutrients*, 15(11):2633, 2023.
- [45] M. Thompson *et al.* Omega-3 fatty acid intake by age, gender, and pregnancy status in the United States: National health and nutrition examination survey 2003–2014. *Nutrients*, 11(1):177, 2019.
- [46] M. I. Martínez-Martínez, A. Alegre-Martínez, and O. Cauli. Omega-3 long-chain polyunsaturated fatty acids intake in children: the role of family-related social determinants. *Nutrients*, 12(11):3455, 2020.
- [47] P. Gareri. Omega-3 Long-Chain Polyunsaturated Fatty Acids in the Elderly: A Review. *OBM Geriatrics*, 6(2):1–28, 2022.
- [48] H. Jiang *et al.* Dietary omega-3 polyunsaturated fatty acids and fish intake and risk of age-related macular degeneration. *Clinical Nutrition*, 40(12):5662–5673, 2021.
- [49] X. Zhang, J. A. Ritonja, N. Zhou, B. E. Chen, and X. Li. Omega-3 polyunsaturated fatty acids intake and blood pressure: a dose-response meta-analysis of randomized controlled trials. *Journal of the American Heart Association*, 11(11):e025071, 2022.
- [50] A. C. Skulas-Ray *et al.* Omega-3 fatty acids for the management of hypertriglyceridemia: a science advisory from the American Heart Association. *Circulation*, 140(12):e673–e691, 2019.
- [51] J. P.-C. Chang *et al.* Safety of supplementation of omega-3 polyunsaturated fatty acids (PUFAs): a systematic review and meta-analysis of randomized controlled trials. *Adv. Nutr.*, 14(6):1326–1336, 2023.
- [52] N. Erdinest, H. Ovidia, R. Kormas, and A. Solomon. Anti-inflammatory effects of resolvin-D1 on human corneal epithelial cells: in vitro study. *Journal of Inflammation*, 11:1–11, 2014.
- [53] U. Hampel, M. Krüger, C. Kunnen, F. Garreis, M. Willcox, and F. Paulsen. In vitro effects of docosahexaenoic and eicosapentaenoic acid on human meibomian gland epithelial cells. *Experimental eye research*, 140:139–148, 2015.

- [54] J.-Y. Hyon and S.-B. Han. The protective effect of polyunsaturated fatty acids against dry eye disease: a literature review. *Applied Sciences*, 11(10):4519, 2021.
- [55] G. Giannaccare *et al.* Efficacy of omega-3 fatty acid supplementation for treatment of dry eye disease: a meta-analysis of randomized clinical trials. *Cornea*, 38(5):565–573, 2019.
- [56] C. O’Byrne and M. O’Keeffe. Omega-3 fatty acids in the management of dry eye disease—An updated systematic review and meta-analysis. *Acta ophthalmologica*, 101(2):e118–e134, 2023.
- [57] S. D. Walter, K. Gronert, A. L McClellan, R. C. Levitt, K. D. Sarantopoulos, and A. Galor. ω -3 tear film lipids correlate with clinical measures of dry eye. *Investigative ophthalmology & visual science*, 57(6):2472–2478, 2016.
- [58] S. Viau *et al.* Efficacy of a 2-month dietary supplementation with polyunsaturated fatty acids in dry eye induced by scopolamine in a rat model. *Graefe’s Archive for Clinical and Experimental Ophthalmology*, 247:1039–1050, 2009.
- [59] C. Schnebelen *et al.* Nutrition for the eye: different susceptibility of the retina and the lacrimal gland to dietary omega-6 and omega-3 polyunsaturated fatty acid incorporation. *Ophthalmic Research*, 41(4):216–224, 2009.
- [60] A. Alhatem, B. Cavalcanti, and P. Hamrah. In vivo confocal microscopy in dry eye disease and related conditions. In *Seminars in ophthalmology*, volume 27, pages 138–148. Taylor & Francis, 2012.
- [61] H. R. Chinnery, C. Naranjo Golborne, and L. E. Downie. Omega-3 supplementation is neuroprotective to corneal nerves in dry eye disease: a pilot study. *Ophthalmic and Physiological Optics*, 37(4):473–481, 2017.
- [62] J. C. Wojtowicz, I. Butovich, E. Uchiyama, J. Aronowicz, S. Agee, and J. P. McCulley. Pilot, prospective, randomized, double-masked, placebo-controlled clinical trial of an omega-3 supplement for dry eye. *Cornea*, 30(3):308–314, 2011.
- [63] H. Kangari *et al.* Short-term consumption of oral omega-3 and dry eye syndrome. *Ophthalmology*, 120(11):2191–2196, 2013.
- [64] R. Bhargava, P. Kumar, H. Phogat, A. Kaur, and M. Kumar. Oral omega-3 fatty acids treatment in computer vision syndrome related dry eye. *Contact Lens and Anterior Eye*, 38(3):206–210, 2015.
- [65] T. Kawakita, F. Kawabata, T. Tsuji, M. Kawashima, S. Shimmura, and K. Tsubota. Effects of dietary supplementation with fish oil on dry eye syndrome subjects: randomized controlled trial. *Biomedical Research*, 34(5):215–220, 2013.
- [66] R. Bhargava, M. Chandra, U. Bansal, D. Singh, S. Ranjan, and S. Sharma. A randomized controlled trial of omega-3 fatty acids in rosacea patients with dry eye symptoms. *Current eye research*, 41(10):1274–1280, 2016.
- [67] M. S. Macsai. The role of omega-3 dietary supplementation in blepharitis and meibomian gland dysfunction (an AOS thesis). *Transactions of the American Ophthalmological Society*, 106:336, 2008.
- [68] Y. J. Jo and J. S. Lee. Effects of dietary high dose DHA omega-3 supplement in dry eye with meibomian gland dysfunction. *International Journal of Ophthalmology*, 14(11):1700, 2021.
- [69] Dry Eye Assessment & Management Study Research Group. n-3 Fatty acid supplementation for the treatment of dry eye disease. *New England Journal of Medicine*, 378(18):1681–1690, 2018.
- [70] J. He and H. E. P. Bazan. Omega-3 fatty acids in dry eye and corneal nerve regeneration after refractive surgery. *Prostaglandins, Leukotrienes and Essential Fatty Acids (PLEFA)*, 82(4-6):319–325, 2010.
- [71] J. A. Hovanesian, S. S. Shah, and R. K. Maloney. Symptoms of dry eye and recurrent erosion syndrome after refractive surgery. *Journal of Cataract & Refractive Surgery*, 27(4):577–584, 2001.
- [72] J. C. Erie, J. W. McLaren, D. O. Hodge, and W. M. Bourne. Recovery of corneal subbasal nerve density after PRK and LASIK. *American journal of ophthalmology*, 140(6):1059–1064, 2005.
- [73] R. Levi-Montalcini. The nerve growth factor 35 years later. *Science*, 237(4819):1154–1162, 1987.
- [74] N. Li, J. He, C. E. Schwartz, P. Gjorstrup, and H. E. P. Bazan. Resolvin E1 improves tear production and decreases inflammation in a dry eye mouse model. *Journal of ocular pharmacology and therapeutics*, 26(5):431–439, 2010.