

## Impacted Deciduous Second Mandibular Molar Tooth

Tahrir N. Aldelaimi<sup>1,\*</sup> and Afrah A. Khalil<sup>2</sup>

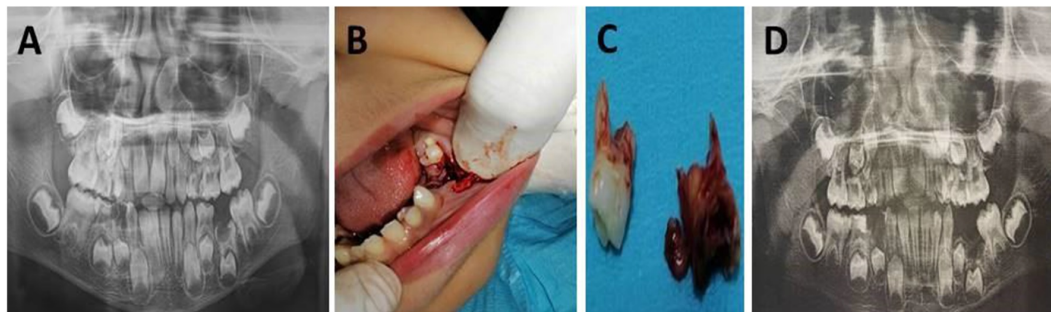
<sup>1</sup>Department of Oral and Maxillofacial Surgery, College of Dentistry, University of Anbar, Ramadi, Anbar, Iraq

<sup>2</sup>Department of Oral Diagnosis, College of Dentistry, University of Anbar, Ramadi, Anbar, Iraq

(Received : 19 November 2021; Accepted : 18 December 2021; First published online: 20 January 2022)

DOI: [10.33091/amj.2023.178336](https://doi.org/10.33091/amj.2023.178336)

© 2023, Al-Anbar Medical Journal



**A** 9-years-old boy presented to the Department of Oral and Maxillofacial Surgery with pain in the posterior region of the left mandible. The child was healthy with an unremarkable medical history. There was no family history of the same condition. Intra-oral clinical examination showed the absence of lower left deciduous molar and multiple carious deciduous teeth at both dental arches. Orthopantomogram (OPG) confirmed the complete impaction of the lower-left deciduous 2nd molar with inferior retention of the lower 2nd permanent premolar close to the lower border of the mandible [Panel A]. Under local anesthesia, a two-sided flap was raised, surgical removal of the impacted deciduous 2nd molar and extraction of adjacent 1st deciduous molar, the flap was sutured with 3/0 silk suture [Panel B and C]. Failure of eruption or impaction of deciduous molar was linked to the disturbance of the development of the successor's permanent teeth. Deciduous tooth failure of eruption or impaction is rare in comparison with permanent teeth. Among deciduous dentitions, the 2nd molar was the most commonly affected tooth, followed by central incisors. Impaction can cause many serious problems to underlying tooth buds of the permanent dentition including their delayed eruption or even ectopic eruption. Therefore, proper history and clinical examination, and precise treatment are mandatory. After one month, OPG showed complete healing [Panel D] and the patient was satisfied with the aesthetic and functional outcomes.

\* Corresponding author: E-mail: [tahrir.aldelaimi@uoanbar.edu.iq](mailto:tahrir.aldelaimi@uoanbar.edu.iq)  
Phone number: +9647819706776