

## Compound Odontoma Associated with Dentigerous Cyst

Tahrir N. Aldelaimi<sup>1,\*</sup> and Afrah A. Khalil<sup>2</sup>

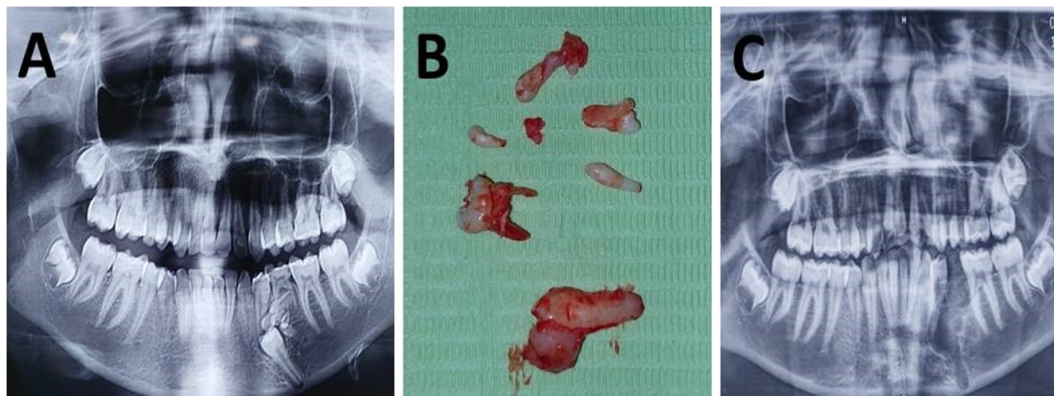
<sup>1</sup>Department of Oral and Maxillofacial Surgery, College of Dentistry, University of Anbar, Ramadi, Anbar, Iraq

<sup>2</sup>Department of Oral Diagnosis, College of Dentistry, University of Anbar, Ramadi, Anbar, Iraq

(Received : 19 September 2021; Accepted : 30 November 2021; First published online: 15 January 2022)

DOI: [10.33091/amj.2022.176315](https://doi.org/10.33091/amj.2022.176315)

© 2022, Al-Anbar Medical Journal



**A** 17-year-old female presented to the Department of Oral and Maxillofacial Surgery complaining of hard expansion with pain sensation in the posterior part of the left mandible for two weeks ago. She was healthy with an unremarkable medical history. Intra-oral examination revealed retained lower left deciduous molar (#75) with bony expansion on the left side of the mandible. Orthopantomograph (OPG) showed unerupted third molars as well as compound odontoma associated with dentigerous cyst include the cement-enamel junction of impacted lower left second premolar leading to mechanical obstacle of eruption and in turn impaction (Panel A). Under local anesthesia, two sided flap was raised, surgical removal of impacted tooth with cyst enucleation, and curettage of the surrounding odontoma tissues (Panel B) with preservation of the inferior dental canal (Panel C). Odontomas are hamartomas that presented as complex or compound odontomas; their etiology still unknown. Compound odontoma was a malformation having more orderly arranged dental tissue pattern that was rarely associated with dentigerous cyst of impacted premolars. The early diagnosis and management of odontoma and cyst are important for both surgeon and patient to avoid the need for surgical intervention and the need for future Prosthodontic restoration of extracted teeth. At the end of six weeks, results showed complete healing and the patient retained her normal sensation with good aesthetic outcome.

\* Corresponding author: E-mail: [tahrir.aldelaimi@uoanbar.edu.iq](mailto:tahrir.aldelaimi@uoanbar.edu.iq)  
Phone number: +9647819706776