

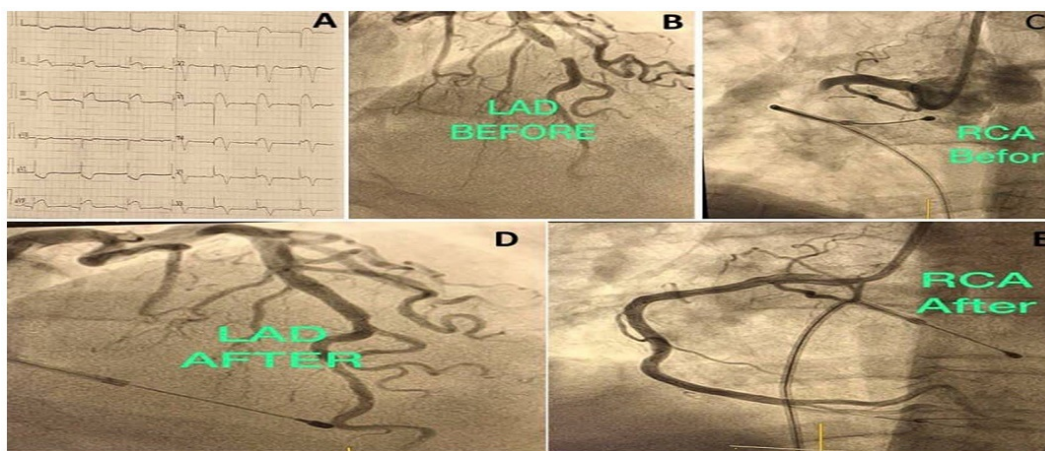
## Occlusion of Two Coronary Arteries Simultaneously

Amjed Sheet\*

Department of Medicine/Cardiology, Al-Ramadi Teaching Hospital, Anbar Health Directorate, Anbar, Iraq.  
(Received : 10 January 2022; Accepted : 15 June 2022; First published online: 4 August 2022)

DOI: [10.33091/amj.2022.176317](https://doi.org/10.33091/amj.2022.176317)

© 2022, Al-Anbar Medical Journal



**A** 60-year-old woman with a history of stroke and known hypertension presented to the emergency room after experiencing acute chest pain for an hour. Her blood pressure was 80/55 mmHg, and her pulse rate was 42 beats per minute. An electrocardiogram (ECG) showed first-degree cardiac block and inferior and anteroseptal leads with acute ST-elevation myocardial infarction (STEMI) (Panel A). The patient was promptly moved to the catheterization lab after receiving first care. Early distal left anterior descending (LAD) artery partial blockage with thrombus-containing lesion was found during diagnostic coronary angiography (Panel B). After a challenging engagement of the right coronary artery (RCA), it was discovered that there was a proximal complete blockage with a thrombus-containing lesion (Panel C). Unfortunately, the patient collapsed with severe bradycardia (34 beats per minute) and hypotension (systolic blood pressure = 60 mmHg), which did not react to quick intravenous fluid and atropine ampules. A temporary pacemaker was soon implanted. After the pacing was started, the patient developed ventricular fibrillation, which required cardiopulmonary resuscitation (CPR) and successive DC shocks before the pulse returned to sinus. The RCA was successfully stented quickly, followed by the stenting of the LAD lesion (Panel D and E). The patient rapidly returns to sinus rhythm with great coronary blood flow, and normal blood pressure is recorded after one hour of recovery. Two hours later, echocardiography demonstrated normal systolic function with no aberrant segmental motion. Occlusion of two coronary arteries is a critical disorder that requires immediate detection and treatment to avoid complications such as ventricular arrhythmias and cardiogenic shock. The patient was released with excellent outcomes.

\* Corresponding author: E-mail: [amjed.sheet@yahoo.com](mailto:amjed.sheet@yahoo.com)  
Phone number: +9647813191270