

Metastatic Ovarian Tumor from Incidental Renal Cell Carcinoma: A Case Report and Literature Review

Shaymaa Khalid Abdulqader,¹ Yousif Ayad Abduljabbar Al-Ani,²
Nabeeha Najatee Akram,³ Wassan Nori,^{4,*} and Mortadha Al-Kinani⁵

¹Department of Radiology, Al-Kindy College of Medicine, University of Baghdad, Baghdad, Iraq.

²Department of Surgery, AL-Yarmouk Teaching Hospital, Baghdad, Iraq.

³Department of Pediatrics, College of Medicine, Mustansiriyah University, Baghdad, Iraq.

⁴Department of Obstetrics and Gynecology, College of Medicine, Mustansiriyah University, Baghdad, Iraq.

⁵Advanced Body MR and Cardiothoracic Fellowship Training at UT Southwestern.

The University of Texas Southwestern Medical Center: Dallas, Texas, USA.

(Received : 7 January 2024; Accepted : 19 March 2024; First published online: 6 April 2024)

ABSTRACT

Renal cell carcinoma (RCC) is the most common solid lesion within the kidney and accounts for most kidney malignancies. The primary tumor size primarily determines the risk of metastasis in RCC. Literature rarely describes metastasis in tumors less than 2 cm; in fact, around 1/3 of RCC reported cases had metastatic disease at the time of diagnosis. RCC tends to metastasize to the lung in half of the patients, to the bones or the liver in 1/3 of patients, and the brain in 5% of all cases. RCC can metastasize to almost every organ in the human body. However, their metastases to the ovaries are incredibly uncommon. In this report, we describe a female presented with the smallest RCC (1cm) that metastasized to the ovary in a patient with previously undiagnosed autosomal dominant polycystic kidney disease (ADPKD). This case report aimed to raise physicians' awareness of the possibility of metastasis in RCC regardless of tumor size and that metastatic RCC could be the first presentation of patients with ADPKD.

Keywords: Secondary ovarian tumor; Polycystic kidney; Renal cell carcinoma; Metastasis.

DOI: [10.33091/amj.2024.145878.1521](https://doi.org/10.33091/amj.2024.145878.1521)

© 2024, Al-Anbar Medical Journal



INTRODUCTION

The ovaries are common sites for secondary metastatic tumors. Most primary tumors that tend to metastasize into the ovaries are of the gastrointestinal tract, breast, and cervical carcinoma. Very rarely, renal cell carcinoma (RCC) metastasizes into the ovary [1]. RCCs are a variety of malignant tumors of the renal cortex that have unique clinical, morphologic, and genetic characteristics [2]. Males are twice as likely to have them as females, and they often appear in the 6th and 7th decade [3].

About 1/3 of the RCC cases had metastatic disease at the time of diagnosis. The most common RCC metastatic sites

in decreasing frequency are the lungs, bones, liver, and brain. RCC can metastasize to almost every organ [4, 5]. However, they rarely metastasize to the ovaries [6]. Tumor size primarily determines the risk of metastasis in RCC. Earlier work has described metastasis in tumors less than 2 cm [7, 8].

Ovarian fibro thecomas (OFTs) are solid benign tumors that have an incidence of 1%–4.5% of all ovarian neoplasms [8]. They are primarily a mixture of fibrous and thecomatous elements. OFT are often unilateral, hormonally inactive, and present in women in their fifth decade. Pain due to compression of different organs is the most frequent presentation. Serum CA-125 values are typically within the normal range in OFT cases [9]. Here, we described a case presented with the smallest RCC (1cm) that metastasized to the ovary in a patient with previously undiagnosed autosomal dominant polycystic kidney disease (ADPKD) while being presented with a big OFT, a sex cord-stromal tumor.

* Corresponding author: E-mail: dr.wassan76@uomustansiriyah.edu.iq
This is an open-access article under the CC BY 4.0 license

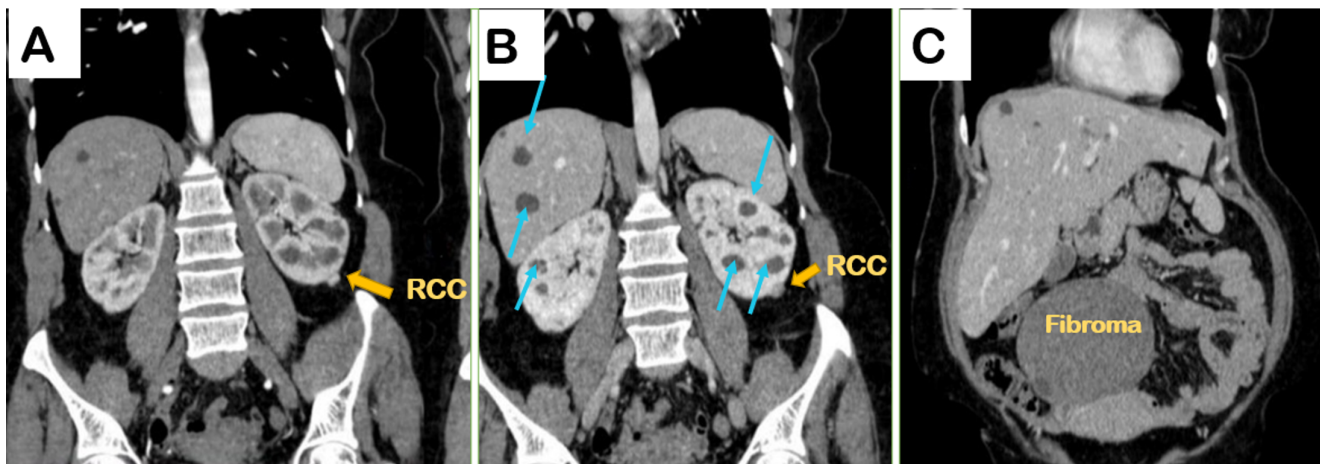


Figure 1. Multiple coronal reformatted sections from a contrast-enhanced computerized tomography scan through the abdomen. A: Corticomedullary phase. B and C: are in the nephrogenic phase. A and B show multiple scattered non-enhancing hepatic and renal cysts highlighted as blue arrows, which confirm the diagnosis of autosomal dominant polycystic kidney disease. Yellow arrows demarcate a small nodule exophytic from the lower pole of the left kidney, which exhibits avid enhancement in the corticomedullary phase and washout in the nephrogenic phase, indicating a primary RCC. Figure 1C: Showing a large right ovarian solid homogenous hypodense mass showing minimal enhancement post-contrast administration, suggesting fibrothecoma.

CASE PRESENTATION

A 45-year-old female presented with severe right abdominal pain for three days. She was G7 P7 A0; the last three babies were delivered by caesarean section; the patient had an unremarkable medical history and a regular menstrual cycle. On examination, there was a right lower abdomino-pelvic hard mass lesion of 6 × 10 cm. An ultrasound examination showed a solid homogenous hypoechoic mass involving the right-side pelvis and lower abdomen, measuring 10.5 × 7 cm, with increased vascularity on color Doppler. It was highly suggested for fibrosarcoma; other differential diagnoses include thecoma, Brenner tumor, and ovarian fibroadenoma.

A pelvic magnetic resonance imaging (MRI) with contrast showed a clear, homogeneous, low-intensity mass at T1 and T2 coming from the right ovary, with only a small amount of enhancement after the contrast was given. The mass measured 11 × 10 × 8 cm and was highly suspicious of malignancy.

Oncologist investigations showed: CA-125 = 13 U/mL, CA 19-9 = 4.8 U/ml both in the normal range, and lactate dehydrogenase = 211 U/L (normal range < 214 U/L). Other biochemical and hematological tests were all within the normal range, including renal and liver function tests, random blood sugar, and a normal resting echo study. A computed tomography (CT) scan of the abdomen was done for further evaluation and staging; it revealed multiple variable sizes cysts (from 10-15 mm in diameter), non-enhancing fluid density in the liver, and both kidneys, which was consistent with undiagnosed ADPKD (Figure 1, A and B).

A large right ovarian solid homogenous hypodense mass is suggestive of fibrothecoma (Figure 1 C). Additionally, an incidental small, well-defined exophytic lesion from the lower pole of the left kidney, measuring 10 mm in diameter, was discovered. The lesion showed avid enhancement in the corticomedullary phase and washout in the nephrogenic and delayed

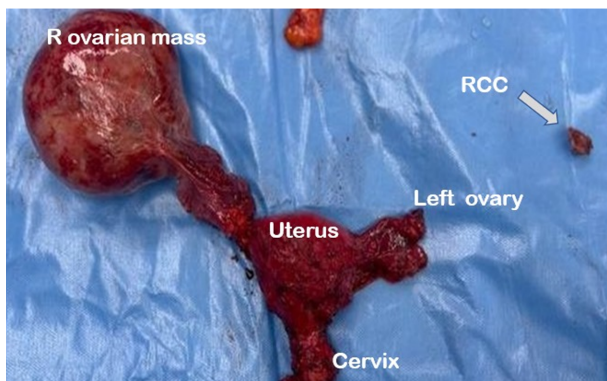


Figure 2. It shows a gross photograph of the total abdominal hysterectomy specimen with bilateral salpingo-oophorectomy, right ovarian fibroma, and small renal cell carcinoma.

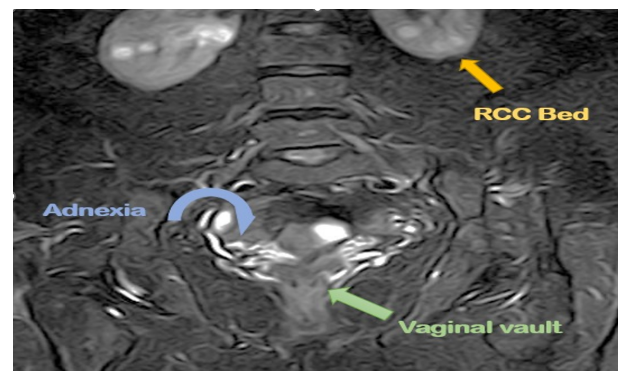


Figure 3. A magnetic resonance imaging coronal T2 fat sat sequence (after 1-year follow-up) shows a normal vaginal vault (green arrow), no adnexal lesion (blue arrow), and a clear bed of the lower pole of the left kidney (yellow arrow).

Table 1. Shows the smallest renal cell carcinoma cases reported in the literature for the last two decades *.

Authors, Publication years	Size of primary kidney Tumor	Site of primary kidney Tumor	Site of Ovarian Metastasis
Takayanagi <i>et al.</i> (2022) [7]	1.6 cm	Rt	Rt
Uruc <i>et al.</i> (2017) [10]	5.8 × 6.8 cm	Rt	Lt
Liang <i>et al.</i> (2016) [11]	8 cm	Rt	Rt
Liang <i>et al.</i> (2016) [11]	8 cm	Lt	Rt
Liang <i>et al.</i> (2016) [11]	7 cm	Rt	Lt
Liang <i>et al.</i> (2016) [11]	7 cm	Rt	Rt
Liang <i>et al.</i> (2016) [11]	9 cm	Lt	Rt
Kostrzewa <i>et al.</i> (2015) [12]	1.5 cm	Lt	Rt
Bohara <i>et al.</i> (2015) [13]	3 × 4 × 5cm	Rt	Rt
Toquero <i>et al.</i> (2009) [14]	4 cm	Lt	Lt
Kato <i>et al.</i> (2006) [15]	4 cm	Lt	Lt

* Rt: right and Lt : left.

phases, which was suspected for a small RCC (Figure 1, A and B).

A laparotomy was undertaken by a joined gynecological and urological team, where a total abdominal hysterectomy, bilateral salpingo-oophorectomy, and removal of the left renal mass were done (Figure 2). The histopathology report of the renal mass was consistent with clear RCC grade II, completely excised with tumor-free margins, and no lymphovascular invasion was identified. The left ovary shows two foci of metastasis from RCC, and the pathological staging was T1a Nx M1. The right ovary shows features of large fibrothecoma; the uterus shows adenomyotic changes. The patient was kept under close follow-up. An abdominal MRI one year after surgery shows a clear renal bed, and no recurrence of the tumor (Figure 3).

DISCUSSION

Metastatic ovarian tumors represent a diagnostic challenge to surgeons; they tend to present late with a worse patient prognosis. Fortunately, this lady had a large primary benign ovarian tumor that urged more detailed evaluation, leading to a small RCC discovery in the left kidney. Imaging tests have promoted women's health in multiple ways [16]. In ADPKD, they help to identify the disease and its extrarenal symptoms, including cystic liver disorders and intracranial aneurysms. Also, they track the disease's development and consequences [17–20].

Many ADPKDs are asymptomatic and accidentally discovered [17]. Researchers believe that the underlying genetic changes causing ADPKD may also contribute to the emergence of RCC. Others proposed that both diseases implicate the intricate interplay of genetic and molecular pathway [18]. The time interval for RCC metastasis had a wide range from 12 weeks to 21 years, which reinforces the importance of routine monitoring and close follow-up for the early detection and treatment of RCC [19, 20].

In this case report, we documented a small RCC in a patient with ADPKD with a rare metastasis to the ovary [8]. This case presented three rarities in one patient.

First, the concomitant number of renal cysts complicates and frequently delays the diagnosis of RCC in individuals with ADPKD, which is why patients with ADPCK rarely observe RCC. When the tumor is tiny, it can often be challenging to distinguish RCC from cyst infection or hemorrhage [21]. Second, our results suggest that the metastatic risk may be higher than reported previously for all tumor sizes [22, 23].

Lastly, RCC rarely metastasizes to the ovaries [23]. Only 40 cases of metastasis to the ovaries were reported from 1957 to 2022. This is considered the 41 case reported till now [7]. Takayanagi *et al.* reported a case of metastatic ovarian tumor five years following the removal of primary RCC; upon retrograde evaluation of the case files, the primary lesion was seen one year earlier as a homogenous enhanced nodule of 10 mm [7].

In Table 1, we summarized the reported RCC cases in the last two decades that were less than 10 cm [7, 10–15].

The identification of two simultaneous ovarian tumors is quite rare. Ibrahim *et al.* reported a 70-year-old woman with a large abdominal mass, which histopathological examination confirmed to be a secondary RCC, a large benign mixed mucinous cystadenoma, and a Brenner tumor [24].

CONCLUSION

This case demonstrates an uncommon RCC presentation that has spread to the ovary in a patient with a big OFT. The presence of a primary ovarian tumor should urge vigorous evaluation since the concomitant presence of two ovarian tumors is not uncommon. ADPKD cases are susceptible to RCC, and RCC cases may exhibit late metastasis years after their excision. Both patients should be carefully followed-up for an earlier diagnosis and better outcome.

ETHICAL DECLARATIONS

Acknowledgements

We appreciate Al Kindy University's support.

Ethics Approval and Consent to Participate

Written approval was gained from the Ethical Approval Committee of Al-Kindy University [IBR (208), dated August 2023]. The patient gave informed consent.

Consent for Publication

Informed consent was granted by the patient for the publication of the case and its images.

Availability of Data and Material

All the data was published.

Competing Interests

The authors declare that there is no conflict of interest.

Funding

No funding.

Authors' Contributions

Each author on the list contributed significantly, directly, and intellectually to the work, and they all agreed on the final manuscript version for publication.

REFERENCES

- [1] R. CK *et al.* Metastatic Tumors to the Ovary Surgeon's Dilemma. *Indian journal of surgical oncology*, 12(1):152–157, 2021.
- [2] J. Rysz, B. Franczyk, J. Lawiński, and A. Gluba-Brzózka. Characteristics of clear cell papillary renal cell carcinoma (ccpRCC). *International Journal of Molecular Sciences*, 23(1):151, 2021.
- [3] T. Makino, S. Kadomoto, K. Izumi, and A. Mizokami. Epidemiology and prevention of renal cell carcinoma. *Cancers*, 14(16):4059, 2022.
- [4] J. L. Mueller, R. A. Guyer, J. T. Adler, and J. T. Mullen. Metastatic renal cell carcinoma to the small bowel: three cases of GI bleeding and a literature review. *CEN Case Reports*, 7:39–43, 2018.
- [5] J. Hołody-Zaręba, P. Kinalski, S. Sulkowski, R. Kozłowski, and M. Kinalski. Bilateral metastases of renal cell carcinoma to the ovaries case report. *Ginekologia Polska*, 84(7), 2013.
- [6] A. Takayanagi *et al.* Imaging findings of ovarian metastasis of primary renal cell carcinoma: A case report and literature review. *Radiology Case Reports*, 17(7):2320–2327, 2022.
- [7] S. M. Monda, H. T. Lui, M. A. Pratsinis, T. Chandrasekar, C. P. Evans, and M. A. Dall'Era. The metastatic risk of renal cell carcinoma by primary tumor size and subtype. *European Urology Open Science*, 52:137–144, 2023.
- [8] M. Horta and T. M. Cunha. Sex cord-stromal tumors of the ovary: a comprehensive review and update for radiologists. *Diagnostic and interventional radiology*, 21(4):277, 2015.
- [9] R. A. Obeidat, A. J. Aleshawi, H. A. Obeidat, and S. M. Al Bashir. A rare presentation of ovarian fibrothecoma in a middle age female: case report. *International Journal of Women's Health*, pages 149–152, 2019.
- [10] F. Urcu, S. Akan, A. Sahin, C. Yildirim, and A. Urkmez. Contralateral ovarian metastasis of clear-cell renal carcinoma: A rare case report and review of the literature. *Case Reports in Surgery*, 2017, 2017.
- [11] L. Liang, H. Huang, V. Dadhanian, J. Zhang, M. Zhang, and J. Liu. Renal cell carcinoma metastatic to the ovary or fallopian tube: a clinicopathological study of 9 cases. *Human pathology*, 51:96–102, 2016.
- [12] M. Kostrzewa, M. Zyla, J. Władziński, T. Stetkiewicz, G. Stachowiak, and J. R. Wilczyński. Metastases of renal clear cell carcinoma to ovary—case report and review of the literature. *Eur J Gynaecol Oncol*, 36(2):219–222, 2015.
- [13] S. Bohara, B. Dey, S. Agarwal, J. N. Bharti, N. Khurana, and P. Sachdeva. Metastatic renal cell carcinoma masquerading as a primary ovarian mass in a post-operative case of meningioma and renal cell carcinoma. *Rare Tumors*, 7(3):111–113, 2015.
- [14] L. Toquero, O. M. Aboumarzouk, and Z. Abbasi. Renal cell carcinoma metastasis to the ovary: a case report. *Cases Journal*, 2:1–4, 2009.
- [15] Y. Kato *et al.* A case of metastatic renal cell carcinoma to the ovary. *Acta Urologica Japonica*, 52(12):923–927, 2006.
- [16] W. N. M. Hassan, F. Shallal, and A. B. Roomi. Prediction of successful Induction of labor using ultrasonic fetal parameters. *Current Women's Health Reviews*, 18(1):134–139, 2022.
- [17] M. Gradzik, M. Niemczyk, M. Gołębiowski, and L. Pączek. Diagnostic imaging of autosomal dominant polycystic kidney disease. *Polish journal of radiology*, 81:441, 2016.
- [18] N. F. Casteleijn *et al.* A stepwise approach for effective management of chronic pain in autosomal-dominant polycystic kidney disease. *Nephrology dialysis transplantation*, 29(4):142–153, 2014.
- [19] A. M. Kase, D. J. George, and S. Ramalingam. Clear cell renal cell carcinoma: from biology to treatment. *Cancers*, 15(3):665, 2023.
- [20] T. ŠIMUNDIĆ, J. PASINI, L. BUBIĆ FILIPI, and T. TURK. RENAL CELL CARCINOMA IN THE AUTOSOMAL DOMINANT POLYCYSTIC KIDNEY DISEASE. *Acta medica Croatica: Časopis Akademije medicinskih znanosti Hrvatske*, 72(4):521–524, 2018.
- [21] Y. Hakoziaki, K. Uchiyama, A. Yanai, D. Yamada, Y. Kamijo, and Y. Ishibashi. Sarcomatoid renal cell carcinoma with autosomal dominant polycystic kidney disease: a case report and literature review. *CEN Case Reports*, 10:199–207, 2021.
- [22] R. Alam, J. J. Tosoian, P. M. Pierorazio, and M. H. Johnson. Distant Metastases From a Small Renal Cell Carcinoma: A Case Report. *Urology Case Reports*, 4:59–60, 2016.
- [23] H. Ohnishi *et al.* Metastatic renal cell carcinoma presenting as multiple pleural tumours. *Respirology*, 10(1):128–131, 2005.
- [24] A. Ibrahim and M. S. Al-Jafari. Metastatic renal cell carcinoma in an ovarian benign mixed mucinous cystadenoma and brenner tumour: a case report. *Case Reports in Pathology*, 2012, 2012.