

Fusion of Maxillary Third Molar with Paramolar Tooth

Tahrir N. Aldelaimi^{1,*} and Afrah A. Khalil²

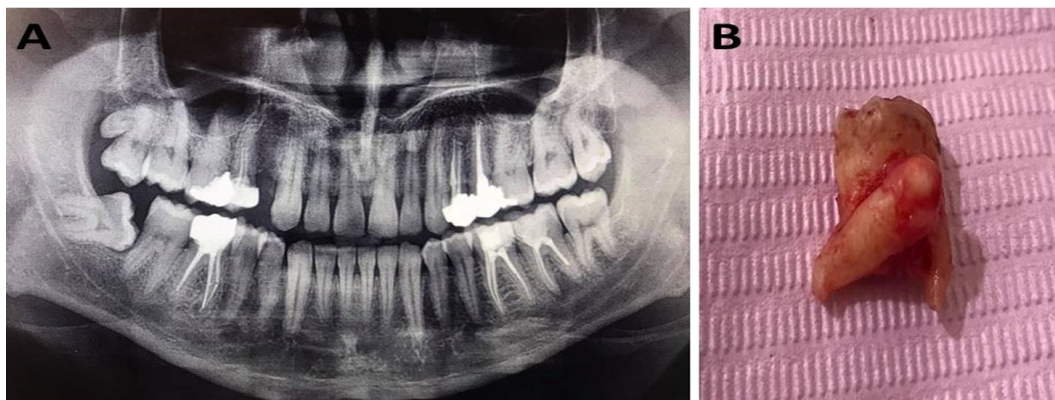
¹Department of Oral and Maxillofacial Surgery, College of Dentistry, University of Anbar, Ramadi, Anbar, Iraq

²Department of Oral Diagnosis, College of Dentistry, University of Anbar, Ramadi, Anbar, Iraq

(Received : 10 February 2021; Accepted : 6 March 2021; First published online: 14 March 2021)

DOI: [10.33091/amj.2021.171076](https://doi.org/10.33091/amj.2021.171076)

© 2021, Al-Anbar Medical Journal



A 35-years-old male was attended the Dental Teaching Clinic of the Department of Oral and Maxillofacial Surgery for surgical extraction of the right upper wisdom tooth. Intra and extra-oral clinical examination as well as orthopantomogram (OPG) interpretation were showed horizontal impacted right lower third molar and erupted upper right third molar with evidence of congenital fusion with the supernumerary (paramolar) tooth. Furthermore, no findings of other orofacial anomalies were noticed and alveolar bone was intact at both maxilla and mandible (Panel A). Under local anesthesia, surgical extraction of the congenital fusion of the maxillary third molar with a supernumerary tooth was done (Panel B). After surgery, the patient was given postoperative verbal instruction of the meticulous oral hygiene practice. The sutures were removed one week later and excellent healing was achieved. Congenital fusion of teeth is the union of both teeth buds that are separated normally. The germination and/or fusion of the molars is uncommon. The prevalence ranges from 0.08% to 0.5%. The upper central incisors are the most frequent teeth involved in fusion and/or gemination (3.55%), followed by the lower wisdom teeth (mandibular third molars) (0.91%). Autosomal dominance probably is the genetic basis for this anomaly. At a one-month follow-up, there was complete healing of the wound without any evidence of complications.

* Corresponding author: E-mail: tahrir.aldelaimi@uoanbar.edu.iq
Phone number: +9647819706776