

## Correlation of Testicular Volume and Semen Parameter with Varicocele Grades in Mosul City: A Case-Control Study

Asaad I Othman\* and Nabeel M Al-Hamamy

Department of Surgery (Urology), Al-Jumhory Teaching hospital,  
Nineveh Health Directorate, Mosul, Nineveh, Iraq.

(Received : 18 August 2020; Accepted : 5 December 2020; First published online: 21 December 2020)

### ABSTRACT

**Background:** Varicocele is a status of abnormal dilatation and sinuosity of the pampiniform plexus that leading to a decrease in the volume of the impacted testicle. Approximately 15-20% and 35% of healthy adult males and men with primary infertility are affected respectively. It was considered as one of the surgically correctible causes of male infertility.

**Objectives:** The objective of the current study was to investigate the correlation of testicular volume and semen parameter with varicocele grades in patients with varicocele attending the Department of Urology of Al-Jumhory Teaching Hospital.

**Materials and methods:** The current study was a case-control study which was conducted in the Department of Urology at Al-Jumhory Teaching hospital, Mosul city, Iraq, during the period January 2018 to June 2019. A total of 250 participants were enrolled in this study (200 patients with clinical varicocele and 50 healthy volunteers). Seminal fluid analysis, testicular size measured by ultrasound scanning, and varicocele grading according to standard criteria based on clinical examination and Doppler study of genitalia were performed for all participants. Statistical analysis was applied to test the correlation of testicular size and seminal fluid parameter with varicocele grade.

**Results:** Patients with varicocele were classified into three groups based on the grade of varicocele: Group I included 22 patients with Grade I varicocele (12%), Group II included 82 patients with Grade II varicocele (38%), and Group III included 96 patients with Grade III varicocele (50%). Besides, Group IV was assigned to healthy volunteers (50) as a control group. Sperms with normal motility and morphology were 33% and 32%, 25% and 25%, 10% and 15%, 60% and 65% in group I, group II, group III, and group IV respectively. There were significant statistical differences (P-value<0.05) between the testicular volumes of both Group II and Grade III and control groups.

**Conclusion:** Men with large varicocele had significantly abnormal semen parameters as well as decreased ipsilateral testicular volumes compared to men with small varicocele or healthy men.

**Keywords:** Male; infertility; Varicocele; Testicular size; Seminal fluid parameters.

DOI: [10.33091/amj.2021.171071](https://doi.org/10.33091/amj.2021.171071)

© 2021, Al-Anbar Medical Journal



### INTRODUCTION

Varicocele is defined as abnormal dilated and tortuous veins of the pampiniform plexus of the spermatic cord [1]. They are more common on the left side, approximately 90% of varicocele is left-sided [1]. Varicocele is the most amenable cause of surgical

correction of male infertility [2]. The prevalence of varicocele about 11-15% among adult men [3] and about 19-41% among infertile men [4]. Despite its unobvious pathophysiology, it may cause progressive damage to the testicle, decreased testicular volume, and disorder of Leydig cell [5]. Formation of varicocele has been attributed to one of the following primary factors: an increase of venous pressure in the left renal vein, anastomoses of collateral venous, and inadequate valves of spermatic vein [1, 6]. The adverse effect of varicocele on spermatogenesis has been attributed to single or integration of

\* Corresponding author: E-mail: [asaaduro@yahoo.com](mailto:asaaduro@yahoo.com)  
Phone number: +9647704504628

additional mechanisms, including hyperthermia, hypoxia, reflux of adrenal and renal metabolites, imbalance of testicular hormonal system, and intra-testicular hyperperfusion damage [1, 7]. Recently, the theory of oxidative stress has been emphasized as an important participation factor due to the presence of an important relationship between species of elevated reactive oxygen and sperm dysfunction in patients with varicocele [8].

Pathologic effect of varicocele may appear as a failure of testicular growth, semen defects, Leydig cell disorder, and other histological changes (tubular thickening, interstitial fibrosis, decreased spermatogenesis, and maturation arrest) [1, 6]. In healthy young men, the normal testicular volume ranges from 15 to 25 ml as about 80% of the testis is composed of seminiferous tubules whereas interstitial tissue takes up 20% of the total testicular volume. Varicocele is associated with a time-dependent growth arrest in adolescents and adult males. Ipsilateral testicular atrophy was founded in 77% of patients with varicocele [1]. The effect of varicocele in testicular function mostly appears in spermatogenesis, in which, the most common finding is sperm count reduction, decreased motility, and an increase in the numbers of morphologically abnormal sperms [1, 7, 8]. Varicoceles with testicular atrophy in patients with infertility have bad semen parameters in comparison with those infertile men without atrophy. Repairing of varicocele would be considered in adolescents with grade II or III of related varicocele with ipsilateral testicular growth impairment [1, 8]. The study aimed to evaluate the correlation of testicular volume and semen parameter with varicocele grades.

## MATERIALS AND METHODS

This case-control study was conducted at the Department of Urology at Al-Jamhory Teaching hospital, Mosul city, Iraq, during the period from January 2018 to June 2019. Two-hundred and fifty people were involved in the study (200 infertile adult men with clinical varicocele and 50 healthy men). Patients excluded from the study including those with azoospermia, undescended testis, patients who previously received treatment for infertility, patients with primary and secondary testicular failure. The study was approved by the scientific committee of our hospital. Informed consent was taken from all participants.

All participants were evaluated by direct interview with a thorough history and clinical examination. Each participant had two seminal fluid analysis done two weeks apart which was collected by masturbation after 3 to 5 days of sexual abstinence. Semen analysis was carried out using the World Health Organization (WHO) 2010 guidelines including sperm concentration, sperm motility, and abnormal morphology. As per the guidelines, normal values are sperm concentration of  $15 \times 10^6$ /ml, progressive motile sperm  $> 32\%$  or total motile sperm  $> 40\%$ , and normal sperm morphology  $> 50\%$ . The presence and the side and grade of varicocele were diagnosed by physical examination at room temperature in supine and standing positions. Scrotal ultrasonography with a high-frequency linear transducer (7.510 MHz) was used for testicular volume measurement. Based on testicular volume, testis was categorized into 3 levels as follows; testis size within average size (18-20 ml), testis size smaller than average size 15-18 ml, and testis size smaller than normal (less than 15 ml). The varicocele patient was assigned according to WHO diagnostic classification and accordingly, we categorized the

patients into three groups, the fourth group involved healthy men was considered as a control group:

Group 1: cases with Grade I varicocele (palpable during Valsalva maneuver).

Group 2: cases with Grade II varicocele (palpable without Valsalva maneuver).

Group 3: cases with Grade III varicocele (palpable and visible veins through the scrotal skin in the upright position without Valsalva maneuvers).

Group 4: control group without varicocele.

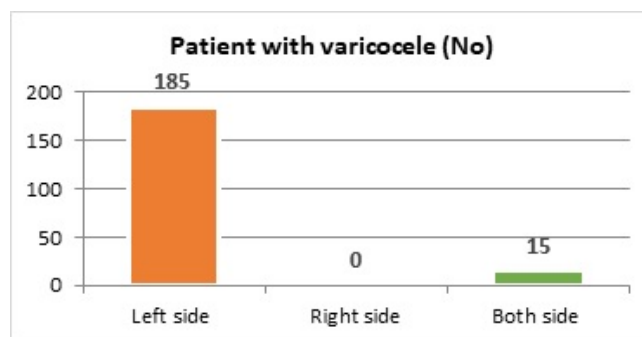
Statistical analyses were performed using Microsoft Excel 2016. Data were presented as means  $\pm$  standard deviation or the frequency and percentage of the data. A student t-test was used for statistical analysis. The level of statistical significance was set at P-value  $< 0.05$ .

## RESULTS

Among 200 patients with idiopathic varicocele, 185 (92%) patients had left-sided varicocele, 15 patients (7.5%) had a bilateral varicocele. No case with pure right-sided varicocele was detected as shown in Figure 1. The classification of the patients according to the varicocele grade and side was shown in Table 1. Testicular size (left and right side) according to varicocele grade presented as mean  $\pm$  SD was described in Table 2. Semen fluid parameters (sperm count, motility, normal sperm morphology) according to a grade of varicocele and normal persons Table 3. The Percentage of testicular volume among varicocele groups were seen in table 4.

As shown in the above Tables (2, 3, 4), patients with grade I varicocele had no significant difference in their testicular volume compared with the control group. Right testicular volumes were within the average size of 18-20 ml in all patients. The left testicular size in 90% of the patients was within average size while it was smaller than average size (18-15) in 10% of the patients. No patient had testicular volume less than the normal range ( $< 15$  ml). When compared with the control group there was no statistically significant (P-value  $> 0.05$ ) regarding testicular volume. Semen parameters in grade I in the most patient (80%) were normal regarding count, motility, and morphology.

In grade II varicocele patients, the right testicular volume in 97.5% of patients was within average size (18-20 ml) and only 2.5% of patients showed testicular volume smaller than average size. The left testicular volume in 67.5% of patients was within average size and 25% of them showed smaller tes-



**Figure 1.** Distribution of patients according to varicocele side (right, left, both sides).

**Table 1.** Number and percentage of varicocele patients according to grade.

Grade	Frequency	Percentages
Grade I	22	11
Grade II	82	41
Grade III	96	48
Total	200	100

**Table 2.** Number of patients with mean testicular volume (right, left side) and statistical difference between groups.<sup>† †</sup>

	No of patients	Left testicular volume (ml)	Right testicular volume (ml)	P-value
Grade I	22	17 ± 4.3	18 ± 5.2	0.02
Grade II	82	15 ± 4.7	15.5 ± 4.7	0.005*
Grade III	96	14 ± 4.5	15 ± 4.8	0.0002*
Control group	50	18.5 ± 4.2	18.6 ± 4.6	Ns <sup>†</sup>

\* significant P-value &lt;0.05

† Not significant P-value &gt;0.05

**Table 3.** Mean sperm concentration, motility, and morphology among groups in the study.

	Sperm concentration / ml±SD	Sperm motility%	Normal Sperm morphology %
Group 1	25×10 <sup>6</sup> ± 4.2	33%	32%
Group 2	20×10 <sup>6</sup> ± 4.1	25%	25%
Group 3	15×10 <sup>6</sup> ± 3.5	10%	15%
Control group	55×10 <sup>6</sup> ± 5.3	60%	65%

**Table 4.** Shows the Percentage of testicular volume among the varicocele group.

Groups	Percentage of Right testicular volume among varicocele groups		
Volume	20-18 ml	18-15 ml	Less than 15 ml
Group 1	100%	–	–
Group 2	97.5%	2.5%	–
Group 3	88%	8%	4%
Groups	Percentage of Left testicular volume among varicocele groups		
Volume	20-18 ml	18-15 ml	Less than 15 ml
Group 1	90%	10%	–
Group 2	67.5%	25%	7.5%
Group 3	29%	53%	18%

ticular volume than average size (18-15 ml) while 7.5% of them have smaller testicles than normal volume (<15 ml). There were significant statistical differences (P-value <0.05) as compared to the testicular volume in the control group. In this group, there was an obvious decrease in both sperm count and motility and an increase in numbers of abnormal sperm morphology.

In grade III, 88%, 8%, and 4% of patients have testicular

volume within the average size, smaller than average size, and smaller than normal, respectively. The left testicular volume in 29% was within the average size, 53% smaller than average size, and 18% smaller than normal volume. There were significant statistical differences (P-value <0.05) when compared with the testicular volume in the control group. Severe oligozoospermia, asthenospermia, and teratozoospermia have been observed in grade III varicocele.

## DISCUSSION

Since the testicle volume was composed of approximately 80% of seminiferous tubules, a large loss in testicle size is a reliable indicator of defects in spermatogenesis [9–11]. Varicocele is a progressive disease with progression dependent injury on the testis [11, 12]. We aimed from our study to determine if there is a correlation between the grade of varicocele and testicular hypotrophy as well as defects in semen parameters. Many authors have shown a correlation between semen parameters and testicular consistency break down over time when varicoceles are not reformed in observational studies in both human and animal models [13]. It appears that with increasing in varicocele grade there is a progressive diminish in testicular size and finally in spermatogenesis. In adults and teens, the size of the testis should approximately be equal bilaterally with no greater than 2 ml of 20% of testicular volume difference to normal values [14]. Testicular volume during or before the teen period always constant, but at the onset of puberty testicular size increases suddenly in size even before other pubertal changes. In teens with varicocele, the rapid growth of testicular size ranged between the ages of 11 and 16 is affected directly by varicocele resulting in a volume disagreement between the left and right testis [15].

In adult men, varicocele studies have shown that the degree of testis atrophy is proportional to the clinical grade of varicocele. Zini et al showed that the size of the left testis affected inversely with varicocele grade [16]. Report of WHO indicated that left-sided varicocele was associated relatively with left testicular atrophy as compared with the contralateral testis [17]). Jay shows that varicocele may affect testicular volume at the affected side in relationship with varicocele grade [18]. Chandra Singh in his study did not reveal any significant correlation between varicocele grade and volume of testis [19]. Pinto et al. noticed that the difference in left and right testicular volume was slight in fertile men with varicocele in comparison with infertile men associated with varicocele [10]. KASS, in his study, had concluded that the appearance of a grade I varicocele does not affect the normal volume of the testis. Grade II left side varicocele patients have a risk of left testicular growth impairment whereas patients with grade III varicocele are at risk of bilateral testicular volume loss [20]. In regards to semen parameters (decreased sperm concentrations, decreased motility, and abnormalities in sperm morphology) concerning varicocele grade, our study has shown that 20% of patients with Grade I varicocele, 72% of patients with Grade II varicocele, and 86% of patients with Grade III varicocele have abnormal seminal fluid parameters.

Our results were somewhat comparable to that of Schlesinger et al. who found that seminal fluid abnormality was 34% in grade I varicocele, 66% in grade II varicocele, and 83% in grade III varicocele [21]. Besides, Sigman and Jarow reported that men affected with large varicoceles resort to have decreased sperm counts and motility defect in comparison with smaller varicoceles [22].

In this study, there was a significant correlation between semen parameter abnormality and varicocele grade. We observed ipsilateral left testicular hypotrophy in 10%, 32.5%, and 71% of patients with grade I, II, and III varicocele, respectively, while the right testicular size was within average normal size as compared with the control group. Steeno observed a loss of testicular volume ipsilateral to the varicocele side, most often the left testis, he showed that grade I varicocele group have no volume loss, grade II had 34% volume loss while Grade III had 81% testicular volume loss [23]. Sigman and Jarow in another series looked retrospectively at 611 adult patients affected with left varicocele, they noticed 50% had ipsilateral testicular hypotrophy, from patients with large grade III varicoceles 73% manifested ipsilateral testicular hypotrophy, in comparison to 55% of patients affected with grade II varicocele and 49% of those with grade I varicocele respectively [22]. Consistent with previous studies, our study has demonstrated the presence of a relationship between varicocele grade increasing and the probability of testicular hypotrophy. Most studies have been used right testis as a normal control when they compare the volume of the

two testes because sexual maturity stages vary with testicular volume. In Mosul city, most of the patients who attended the urology and infertility center were grade III, while grade II and I represented about 40% and 10% respectively. Mohammad and Khalid study reported that the grade I, II, and III varicocele group correspond to 5%, 32%, and 63% respectively [24]. This may reflect and explain the harmful effect of high-grade varicocele on the function of the testis. The limitation of our study was a low number of patients from grade I. It appears likely that many cases of low-grade varicocele without concomitant enlargement may remain undiagnosed or not referred for further evaluation [22].

In conclusion, varicocele is a time-dependent progressive disease. Men with large varicoceles had significantly decreased ipsilateral testicular volumes with lower sperm counts, motility, and more abnormal sperm morphology than those with smaller varicoceles. The presence of a grade I varicocele appears to not affect normal testicular volume.

### CONFLICT OF INTEREST

The authors declare that there is no conflict of interest.

### REFERENCES

- [1] A. Agarwal, R. Sharma, A. Harlev, and S. C. Esteves. Effect of varicocele on semen characteristics according to the new 2010 world health organization criteria: a systematic review and meta-analysis. *Asian J. Androl.*, 18(2):163, 2016.
- [2] H. Wang, X. Wang, D. Fu, H. Zhu, and M. Lai. Does varicocele grade predict the postoperative changes of semen parameters following left inguinal micro-varicocelectomy? *Asian J. Urol.*, 2(3):163–166, 2015.
- [3] W. H. Organization. The influence of varicocele on parameters of fertility in a large group of men presenting to infertility clinics. *Fertil. Steril.*, 57(6):1289–1293, 1992.
- [4] W. F. Hendry, I. F. Sommerville, R. R. Hall, and R. C. B. Pugh. Investigation and treatment of the subfertile male. *Br. J. Urol.*, 45(6):684–692, 1973.
- [5] K. U. Rehman *et al.* Correlation between testicular hemodynamic and semen quality indices in clinical varicocele patients in pakistan. *Biomed Res. Int.*, 2019.
- [6] C. K. Naughton, A. K. Nangia, and A. Agarwal. Varicocele and male infertility: part ii: pathophysiology of varicoceles in male infertility. *Hum. Reprod. Update*, 7(5):473–481, 2001.
- [7] D. A. Paduch and S. J. Skoog. Diagnosis, evaluation, and treatment of adolescent varicocele. *Scientific World Journal*, 4, 2004.
- [8] S. M. H. Arraki. Evaluation of the effect of varicocelectomy on semen parameters and fertility. *Diyala J. Med.*, 11(2):34–43, 2016.
- [9] A. Zini, M. Buckspan, D. Berardinucci, and K. Jarvi. The influence of clinical and subclinical varicocele on testicular volume. *Fertil. Steril.*, 68(4):671674, 1997.
- [10] K. J. Pinto, R. Lawrence Kroovand, and J. P. Jarow. Varicocele related testicular atrophy and its predictive effect upon fertility. *J. Urol.*, 152(2):788–790, 1994.
- [11] S. M. Petak, H. R. Nankin, R. F. Spark, R. S. Swerdloff, and L. J. Rodriguez-Rigau. American association of clinical endocrinologists medical guidelines for clinical practice for the evaluation and treatment of hypogonadism in adult male patients—2002 update. *Endocr. Pract. Off. J. Am. Coll. Endocrinol. Am. Assoc. Clin. Endocrinol.*, 8(6):440–456, 2002.
- [12] M. A. Witt and L. I. Lipshultz. Varicocele: a progressive or static lesion? *Urology*, 42(5):541–543, 1993.
- [13] E. W. Salzhauer, A. Sokol, and K. I. Glassberg. Paternity after adolescent varicocele repair. *Pediatrics*, 114(6):1631–1633, 2004.
- [14] E. J. Kass. The evaluation and management of the adolescent with a varicocele. *AUA Updat. Ser.*, 12:90–95, 1990.
- [15] S. V Krishna Reddy, A. Basha Shaik, S. Sailaja, and M. Venkataramanaiah. Outcome of varicocelectomy with different degrees of clinical varicocele in infertile male. *Adv. Androl.*, 2015.
- [16] A. Zini, M. Buckspan, D. Berardinucci, and K. Jarvi. Loss of left testicular volume in men with clinical left varicocele: correlation with grade of varicocele. *Arch. Androl.*, 41(1):37–41, 1998.
- [17] A. Agarwal, S. Prabakaran, and S. C. Sikka. Current opinions on varicocele and oxidative stress and its role in male infertility. *US Genitourin. Dis.*, page 6268, 2006.
- [18] J. I. Sandlow. Do varicoceles really affect male fertility? *Sex. Reprod. Menopause*, 2(4):219–221, 2004.
- [19] J. C. Singh and N. Kekre. Does testicular hypotrophy correlate with grade of adolescent varicocele? *Indian J. Urol.*, 21(2), 2005.
- [20] E. J. Kass, B. R. Stork, and B. W. Steinert. Varicocele in adolescence induces left and right testicular volume loss. *BJU Int.*, 87(6):499–501, 2001.
- [21] M. H. Schlesinger, I. F. Wilets, and H. M. Nagler. Treatment outcome after varicocelectomy. a critical analysis. *Urol. Clin. North Am.*, 21(3):517–529, 1994.
- [22] M. Sigman and J. P. Jarow. Ipsilateral testicular hypotrophy is associated with decreased sperm counts in infertile men with varicoceles. *J. Urol.*, 158(2):605–607,

- 1997.
- [23] O. Steeno, J. Knops, L. Declerck, A. Adimoelja, and H. Van de Voorde. Prevention of fertility disorders by detection and treatment of varicocele at school and college age. *Andrologia*, 8(1):47–53, 1976.
- [24] Mohammad Rauf Shaikh and Khalid Ahsan Malik. Varicocelectomy. *Pakistan journal of surgery*, 22(3):139, 2006.