

Bilateral Auricular Trichoepitheliomas

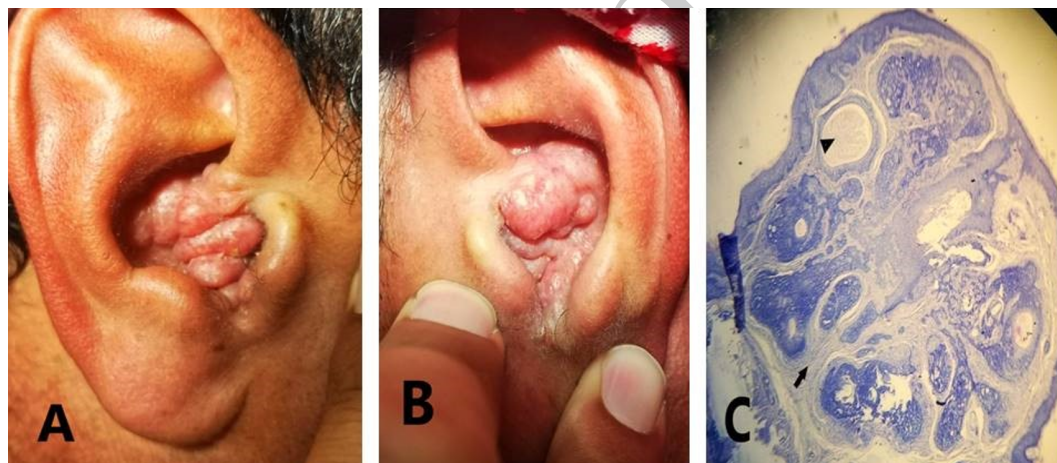
Khalid M. Awad¹ and Omar M. Bargas^{2,*}

¹Department of Medicine/Dermatology and Venereology,
Ramadi Teaching Hospital, Anbar Health Directorate, Anbar, Iraq

²Department of Surgery/Otolaryngology, College of Medicine, University of Anbar, Anbar, Iraq
(Received : 9 May 2023; Accepted : 25 June 2023; First published online: 31 August 2023)

DOI: 10.33091/amj.2023.140234.1142

© 2023, Al-Anbar Medical Journal



A 34-year-old male presented to the Dermatology Clinic complaining of unsightly bilateral auricular growths (Panels A and B) obstructing the external auditory meatus and sparing the face. The lesions are characterized by multiple asymptomatic, firm, pink, and scaly papules. An otolaryngologist was then consulted to assess the extent of the lesion. This was found to involve the outer ear canal part, resulting in aural fullness with no discharge or tinnitus. No other otological findings were seen. A punch biopsy was done, and it revealed a superficial dermal tumor with prominent keratinized horn cysts (Black arrowhead) and fibrous stroma (Black arrow) (Panel C: H&E X 40), which correlates with a trichoepithelioma diagnosis. Trichoepithelioma is a rare and benign skin tumor, mostly found on the face. It is thought to arise from the hair follicle wall and is characterized by benign epithelial and mesenchymal proliferation. Aside from facial involvement, a few auricular cases were reported, some of which involved both auricles while others involved one auricle. Females are affected more than males and may be predisposed to psychological upset. It may be solitary, multiple, or desmoplastic. Complete surgical excision remains the mainstay of treatment in these cases. Although a CO₂ laser may be used to debulk the tumor, it usually regrows. The decision of surgical excision with skin grafting was presented to the patient, however, the patient declined the surgical intervention.

* Corresponding author: E-mail: omar.alrawi@uoanbar.edu.iq
Phone number: +9647803388198