

Atypical Presentation of Pelvic Abscess: A Case Report

Haitham Noaman^{1,*} and Ammar Fouad²

¹Department of Medicine/Internal Medicine, College of Medicine, University of Anbar, Ramadi, Anbar, Iraq.

²Department of Surgery/General Surgery, AL-Yarmouk Teaching Hospital, Baghdad, Iraq.

(Received : 28 June 2022; Accepted : 31 October 2022; First published online: 24 November 2022)

ABSTRACT

An abscess is a common disease worldwide and its diagnosis is usually straightforward. However, pelvic abscess is rarely seen in daily clinical practice. Besides, it is a challenge for the surgeon to diagnose abscesses in unusual location, including the pelvis. A 41-year-old housewife lady had a history of poorly controlled insulin-dependent diabetes mellitus with recurrent vaginitis, cervicitis, and recurrent urinary tract infection. She presented with bilateral hip joint pain and limitation in her movement, with diabetic ketoacidosis. She was admitted to the hospital for the treatment of diabetic ketoacidosis. A physical examination revealed a high-grade fever, unwell, and there is a pelvic mass. Laboratory tests showed leukocytosis and a low hemoglobin level. Ultrasonography and computerized tomography revealed a 5 × 5 pelvic mass, which was located anterior to the bladder, with a high suspicion of an abscess formation. The patient was admitted to the surgical ward and drainage of the abscess under general anesthesia with antibiotic cover was performed. The patient was discharged two weeks postoperatively with an improvement in all presenting features. Bilateral insidious hip joint pain with limitation of movement should orient the clinician to a pelvic abscess as one of the differential diagnoses of these symptoms.

Keywords: Pelvic Abscess; Ketoacidosis; Surgery; Case report.

DOI: [10.33091/amj.2022.176313](https://doi.org/10.33091/amj.2022.176313)

© 2022, Al-Anbar Medical Journal



INTRODUCTION

An abscess is a pus collection bounded by inflammatory tissue. It is a common condition and can occur anywhere in the body. However, pelvic abscess is relatively rare. Pelvic abscesses most commonly follow either acute appendicitis, obstetric infections, or procedures [1]. It can also occur as a complication of diverticulitis or following abdominal surgery, or Crohn's disease [2, 3]. It is characterized by fever, unwell feelings, abdominal pain, and a palpable mass on the pelvic examination. Other features include pain exacerbation at movement, pain at or following sex, constipation or diarrhea mixed with mucus, physical weakness, emotional exhaustion, abdominal bloating, inability to raise the leg or limping, according to the abscess position, vaginal discharge, pain occurring at flatus or defecation, extreme pelvic pain, and

lower abdominal pain [4, 5]. And an increase in the number of white blood cells (leucocytosis) [1]. However, groin pain may be the only sign of a large pelvic abscess [1]. Also, pelvic abscess results from severe genital tract infection. In such cases, the abscess occupies the pelvis and may extend to the lower abdomen, it is commonly posterior to the uterus and surrounded by the loops of the small bowel, sigmoid colon, cul-de-sac, and walls of the pelvis on each side (<https://www.kegel8.co.uk/advice/pelvic-pain/causes-and-diagnosis-of-pelvic-pain/pelvic-abscess.html>).

Previous studies show that routine cultures do not change the management or outcome of pelvic abscesses (<https://emedicine.medscape.com/article/1979032-clinical>). The differential diagnosis of the pelvic abscess may include a malignant mass from adjacent organs [6] and tuberculoma mass [7]. Hence, we presented a 41-year-old woman with a pelvic abscess to highlight the approach to the pelvic abscess and how to exclude other differential diagnoses.

* Corresponding author: E-mail: med.haitham.numan@uoanbar.edu.iq
Phone number: +9647902528415

CASE PRESENTATION

A 41-year-old Iraqi housewife who lives in Baghdad, the capital city of Iraq, presented to a private internal medicine clinic in March 2022 with pain in both hip joints and abnormal gate posture after a strenuous long-distance walk with generalized ill health. She has been known case of insulin-dependent diabetes mellitus (IDDM) for more than 20 years with poor control of her blood sugar. She gave a history of cauterization to her cervix two weeks before her presentation. On examination, she was dehydrated with a ketone smell, with a tender vague lower abdominal mass. She was admitted to Al-Yarmouk Teaching Hospital for the treatment of diabetic ketoacidosis, which was treated successfully. Then she was reevaluated for her hip pain and pelvic mass. Physical examination showed that her blood pressure was 100/60mmHg, pulse rate was 120 beats per minute, and her respiratory rate was 18/minute. The axillary body temperature was 38.6°C. An abdominal exam revealed a soft abdomen with a lower abdominal vague mass about 5 × 5 cm with tenderness, non-pulsatile, and fluctuation and transillumination tests were negative. A Locomotors exam revealed her hip joint movement was limited in all directions. A complete blood picture showed hemoglobin of 14 gm/dL, white blood cells $7.14 \times 10^9/L$, platelets 350×10^3 , creatinine 0.5 mg/dl, blood urea 22.4 mg/dl, and random blood sugar 175 mg/dl. Meanwhile, the orthopedic surgeon reported that the symptoms were not related to both hips.

The patient was sent for an abdominal and pelvic ultrasound which showed a complex mass lesion of 5.5 × 5 cm is seen in the suprapubic area anterior to the urinary bladder (containing a central echogenic shadow surrounded by fluid), the mass may be related to the bowel as shown in Figure 1. An abdominal CT scan revealed a peripherally enhancing cystic lesion with internal gas foci measuring 39 × 64 × 66 mm seen anterior to the urinary bladder, as well as peripheral fat stranding, indicating an abscess (Figure 2).

Then the patient was referred to the general surgeon and admitted to the surgical ward for assessment and preparation for the operation. The hemoglobin dropped to 10.1 gm/dL, white blood cells elevated to $13.6 \times 10^9/L$ with neutrophilia,

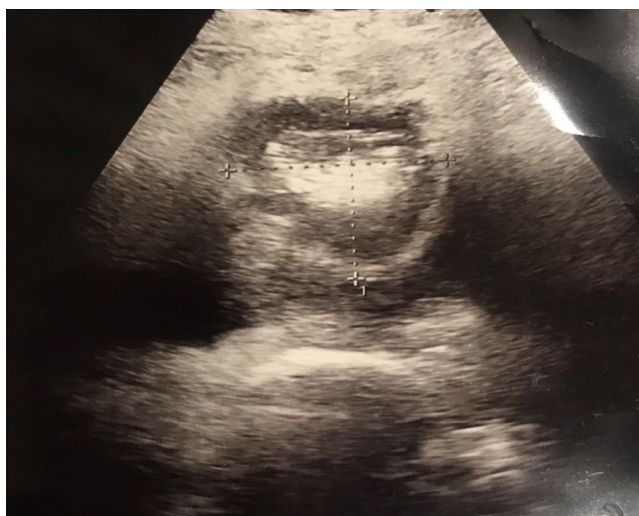

Figure 1. Pelvic ultrasound showed a complex mass lesion of 5.5 × 5 cm in the suprapubic area anterior to the bladder

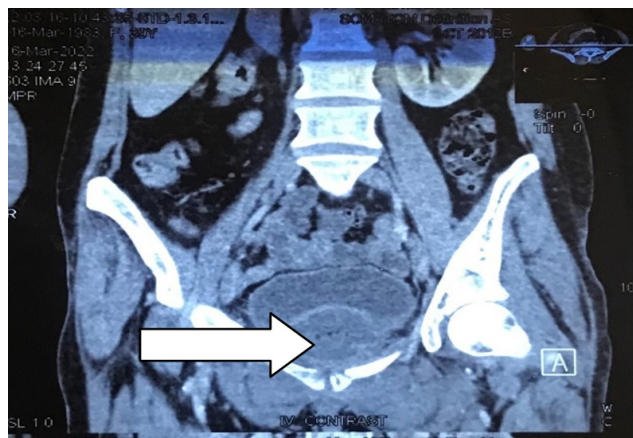


Figure 2. Abdominal computerized tomography scan showed a peripherally enhanced cystic lesion in the suprapubic area anterior to the bladder, suggesting an abscess (white arrow).

and random blood sugar was controlled to 141mg/dl. The patient was put on ceftriaxone intravenous injection, 1 gram twice per day, and metronidazole intravenous injection, 500 mg three times/day. The physician put her on sliding scale soluble insulin management. The gynecologist reported no abnormal findings on the genital system exam. Pelvic MRI showed evidence of well-defined, peripherally enhanced septate collection measuring 39 × 64 × 66 mm seen anterior to the bladder with an intact anterior pubic wall and posterior urinary bladder, a picture suggestive of an abscess with normal abdominal and pelvic organs.

The next morning, we noticed unexpectedly that the pus was draining through the urethral catheter with a mild improvement in her condition. We consulted the urologist, who advised us to keep her on conservative management and to prepare her for a cystogram to define the site of the vesicle fistula. On the next day, the pus stopped discharging from the catheter and the symptoms recurred with fever and increased pain in the lower abdomen and both her hip joints. Therefore, the decision was made to evacuate the abscess immediately. In the operating room, a lower midline laparotomy incision was made, and no abnormal findings were found in the abdominal and pelvic cavities. Therefore, an extension was made through the retropubic space downward anterior to the urinary bladder, the abscess cavity was located, opened, and drained (Figure 3). Part of the cavity wall was excised and sent for histopathology and microbiological study. The urology team opened the urinary bladder and found no clear connection to the abscess cavity. Then the cavity was washed and other drains were also put inside, other drains also placed in the abdominal cavity and the retropubic space and the wounds closed. Following full recovery, the patient was transferred to the surgical ward.

The patient stayed in the hospital for ten days after the operation, with a major improvement in her condition. The fever subsided, she walked well, and the hemoglobin and blood sugar returned to normal. The subcutaneous corrugated drain was removed after 5 days and the tube drain inside the abscess cavity was removed after ten days, except for the urinary catheter. Two weeks postoperatively, a cystogram showed a normal bladder wall. Therefore the urinary catheter was removed. The histopathology report showed a piece of tissue

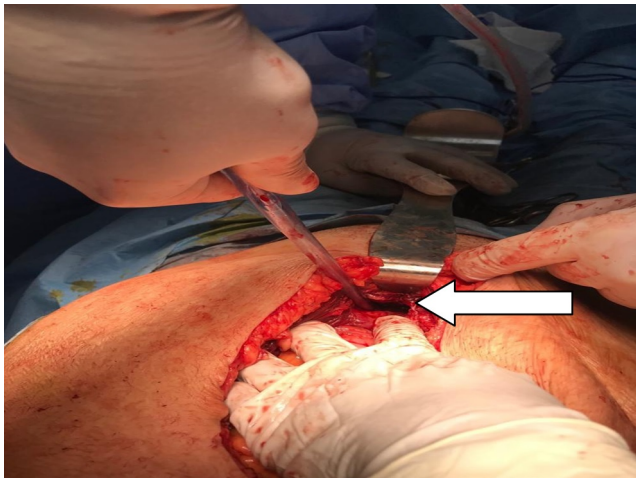


Figure 3. Photographic picture showed the abscess cavity opening with drainage of the pus through a lower median incision.

composed of a fibrous stroma with a scattered mixed inflammatory reaction, Brucella test and real-time polymerase chain reaction for tuberculosis were negative.

DISCUSSION

The pelvic abscess is a rare condition and is usually located posteriorly [8]. However, our case was presented deep in the pelvic region anteriorly. To our best knowledge, the presenting case was first case in the world to be diagnosed with anterior pelvic abscess. Besides, the patient presented with an atypical presentation of pain in both hips of her anterior-located pelvic abscess.

Pain/tenderness, abdominal distention, fever, anorexia, tachycardia, and leukocytosis are common symptoms of an intra-abdominal abscess [1]. However, as we will discuss below, our presenting case had a complex and varied set of features during the hospitalization period.

The gynecologist found that the genital system was normal as well as there were no features of pelvic inflammatory disease. Owing to the patient's having a history of cervical cauterization of an ulcer 2 weeks before her presentation, we think about suspicion of a small perforation in the area with inoculums of bacteria leading to an abscess formation. The symptoms were not severe at an early stage because of the low immunity of the patient (poorly controlled IDDM). At a later stage, there were low grade constitutional symptoms including fever, sweating, and arthralgia. The patient was admitted to control her state of diabetic ketoacidosis. After controlling the blood sugar, the patient complained of bilateral hip pain and gait abnormality. She denied any history of an abnormal gait. Orthopedic examination and investigations revealed no abnormalities in either hip. Then she suffered from lower abdominal pain with a vague mass in the pelvis which was difficult to palpate because the mass lies behind the pubic bones. Abdominal ultrasound showed a complex pelvic mass. As a consequence, we think about differential diagnoses like

tuberculosis, hydatid cyst, and malignancy [9]. We put tuberculosis and hydatid cyst as differential diagnoses because these conditions are endemic in Iraq and may present with abscess and bilateral hip joints [10, 11].

A multidisciplinary team of physicians, general surgeons, gynecologists, and urologists was formed to solve this dilemma case. Following a thorough discussion with full investigations by laboratory tests and imaging studies, we decided to perform an exploratory laparotomy. During surgery an evacuation of a pelvic abscess was done. In addition, malignancy, tuberculosis, hydatid cysts, and fungal infection were excluded.

The ideal approach for pelvic abscess management should be safe, effective, minimally invasive, cost-effective, and it shouldn't affect fertility as much as possible [9]. There are various approaches to draining the pelvic abscess, including laparoscopy, laparotomy, and imaging-guided drainage [8]. Due to the complex presentation of the case, we drained the abscess through a laparotomy approach.

CONCLUSION

Although pelvic abscess is rare, it should be put on the list of differential diagnoses of bilateral hip pain. A full workup (particularly abdominal CT) as in the above steps is required to catch the diagnosis early and treat it promptly.

ETHICAL DECLARATIONS

Acknowledgements

We appreciate Dr. Hanan Hazim consultant of gynecology for her kind help and the urological team of consultant Dr. Mazen AL-Rawi, team for their kind effort and help.

Ethics Approval and Consent to Participate

Written approval had been gained from the Ethical Approval Committee of the University Of Anbar, Anbar governorate, Iraq. The patient provided informed consent.

Consent for Publication

Informed consent from the patient was obtained for the publication of the case and the related images.

Availability of Data and Material

All the data was published.

Competing Interests

The authors declare that there is no conflict of interest.

Funding

No funding.

Authors' Contributions

All of the authors on the list made a significant, direct, and intellectual contribution to the work and gave their permission for it to be published.

REFERENCES

- [1] Sarah A Damer. Pelvic Abscess with Presentation as Inability to Ambulate. *Spartan Medical Research Journal*, 2(2), 2018.
- [2] Christina Korownyk and G Michael Allan. Evidence-based approach to abscess management. *Canadian Family Physician*, 53(10):1680–1684, 2007.
- [3] Ning Zhao, Qian Li, Jing Cui, Zhiyong Yang, and Tao Peng. CT-guided special approaches of drainage for intraabdominal and pelvic abscesses: One single center's experience and review of literature. *Medicine*, 97(42), 2018.
- [4] Seok-Hoo Jeong *et al.* Clinical features of intra-abdominal abscess and intestinal free-wall perforation in Korean patients with Crohn's disease: results from the CONNECT study. *Journal of Clinical Medicine*, 10(1):116, 2020.
- [5] Sarah C Mansour *et al.* Bacterial abscess formation is controlled by the stringent stress response and can be targeted therapeutically. *EBioMedicine*, 12:219–226, 2016.
- [6] Teresa Pusiol, Doriana Morichetti, Corrado Pedrazzani, and Francesco Ricci. Abdominal-pelvic actinomycosis mimicking malignant neoplasm. *Infectious diseases in obstetrics and gynecology*, 2011, 2011.
- [7] Haijiao Wang, Xinglong Qu, Xiaoxia Liu, Lili Ding, and Ying Yue. Female peritoneal tuberculosis with ascites, pelvic mass, or elevated CA 125 mimicking advanced ovarian cancer: A retrospective study of 26 cases. *J Coll Physicians Surg Pak*, 29(6):588–589, 2019.
- [8] Devrim Aknc, Onur Ergun, Çada Topel, Türkmen Çiftçi, and Okan Akhan. Pelvic abscess drainage: outcome with factors affecting the clinical success. *Diagnostic and Interventional Radiology*, 24(3):146, 2018.
- [9] Seth Granberg, Knut Gjelland, and Erling Ekerhovd. The management of pelvic abscess. *Best practice & research Clinical obstetrics & gynaecology*, 23(5):667–678, 2009.
- [10] Haitham Noaman, Salman Rawaf, Azeem Majeed, and Abdul-Majeed Salmasi. Hydatid cyst of the heart. *Angiology*, 68(9):765–768, 2017.
- [11] Raid M Al-Ani. Nasal Tuberculosis in a Teenage Female. *Indian Journal of Otolaryngology and Head & Neck Surgery*, 71(3):2047–2049, 2019.