

Hydatid Cyst Pleural and Pericardial Effusions as a Complication of Postoperative Hydatid Cyst Resection from the Liver: A Case Report

Haitham Noaman^{1,*} and Khalil Sarhan Khalaf²

¹*Department of Internal Medicine, College Of Medicine, University of Anbar, Ramadi, Anbar, Iraq.*

²*Department of Cardiology, Ibn Al-Betar Cardiac Center, Baghdad, Iraq.*

(Received : 17 October 2021; Accepted : 16 December 2021; First published online: 20 January 2022)

ABSTRACT

Hydatid cyst is a zoonotic endemic disease in Iraq. It carries considerable complications either related to the disease itself or following its surgical removal. Pleural and pericardial effusion is a rare postoperative complication of hydatid cyst removal. A 65-year-old Iraqi female patient complained of right-sided chest heaviness and palpitation one month following surgical removal of 2 large hydatid cysts. There were no other associated symptoms. Physical examination revealed the possibility of pleural and pericardial effusions (poor air entry and stony dullness of the right posterior part of lower zone, difficulty to palpate the apex beat, increase heart dullness, and no pericardial rub). The diagnosis was confirmed by chest X-ray and echocardiogram. She received Albendazole tablet 400 mg twice daily for 6 weeks with a good response. The Early presumption of the disease in an endemic area with a good dose and appropriate course of Albendazole tablets treatment can give very good results. To our best knowledge, this is the first case in the world who presented with hydatid cyst pleural and pericardial effusions and responded completely to the Albendazole tablets.

Keywords: Hydatid cyst; Pleural effusion; Pericardial effusion; Albendazole; Case report.

DOI: [10.33091/amj.2022.174531](https://doi.org/10.33091/amj.2022.174531)

© 2022, Al-Anbar Medical Journal



INTRODUCTION

H ydatid cyst is endemic in Iraq with significant morbidity and mortality. The causative parasite is *Echinococcus granulosus* as a larva or cyst form. It parasitized the dogs, where, it gets an infection when consuming the muscles or liver of cattle infected with hydatid cysts. The canids are the main source of transmitting the infection to humans, which is the intermediate host. Hydatid cysts infect the liver in 70%. The next most common site then is the lungs, then if ova enter the systemic circulation, it infects the spleen, brain, or any part in the body. The cyst scenario in the body either collapses and disappears or calcify, where other cysts increased in size, compresses or displace normal tissue and organs, or it may be complicated. The enlargement rate of the cyst is about 1-3cm in diameter per year [1-4].

Hydatid cyst rupture might be presented as pleural and pericardial effusion where these complications if delayed in management may lead to widely disseminated hydatid cyst in pulmonary and cardiac with systemic spread. Therefore, it may lead to fatal outcomes in the ongoing life [4]. We reported a case of pleural and pericardial effusions following resection of a liver hydatid cyst.

CASE PRESENTATION

A 65-year-old Iraqi lady presented to a private cardiac clinic in January 2021 with progressive chest heaviness and palpitation. She is a housewife and lives with her family in the Khan Dhari city (a rural area at the west of Baghdad, the capital of Iraq). There was no chest pain, cough, or fever. She had a history of two months before the presentation with surgical removal of 2 large hydatid cyst of the liver while there was remaining multiple inoperable small hydatid cysts. There was no history of trauma to the upper abdomen. The cardiologist referred the patient to Internist and infectious private clinic in Baghdad for further assessment and management. She was hypertensive on valsartan tablet 160 mg

* Corresponding author: E-mail: med.haitham.numan@uoanbar.edu.iq
Phone number: +9647902528415

daily. No same history was found in her family. Neither she was smoked before, nor any abnormal habits. Her blood pressure was 120/70mmHg, pulse rate 110beats per minute with an irregularly irregular rhythm, pulse deficit 15 beats per minute, and respiratory rate 18 per minute. The axillary body temperature was 36.3°C. Physical examination showed decreased tactile focal fremitus, stony dullness on percussion, and diminish air entry in the posterior part of the right lower chest zone. There was a difficulty to palpate cardiac apex beat, increase cardiac dullness, and no pericardial rub. On abdominal examination, there was hepatomegaly with multiple liver cysts. There was no lymphadenopathy and the rest of the examination was normal. An echocardiogram revealed a moderate amount of pericardial effusion (Figure 1), electrocardiogram (ECG) showed rapid atrial fibrillation (Figure 2), and chest X-ray revealed right-sided pleural effusion and cardiomegaly due to pericardial effusion (Figure 3). A complete blood picture showed: Hemoglobin 11 gm/dL, the mean corpuscular volume 75, white blood cells (WBC) 65000 mcL, platelets 350×10^3 , creatinine 107 mL/min, blood urea nitrogen (BUN) 16 mmol/L, ALT 60 units/L, AST 80 units/L, alkaline phosphatase 59 units/L, albumin 4.5gm%, total bilirubin 1.7 mol/L, and direct bilirubin 0.3 mol/L. Quantiferon (Interferon-gamma release assay) tests were negative. Accordingly, the patient was diagnosed with pericardial and pleural effusions of moderate amounts.

Following the initial assessment and precise review of the investigations, thorough discussion of the case with her primary cardiologist, the highest possible cause of both pleural and pericardial effusions is a rupture of the small hydatid cyst to the pleura and pericardium. We avoided aspiration of the fluid for analysis because this might lead to disseminated hydatid cyst through a tract of aspiration. Therefore, we treated the patient with an Albendazole tablet 400 mg twice daily with further follow-up and assessment for another cause. Computerized tomography (CT) scans of the lung and heart showed only pleural and pericardial effusions, with no remnant cysts or other lesions. After six weeks of treatment, there was an improvement in the presenting symptoms, chest X-ray was normal as shown in Figure 4, and normal echocar-

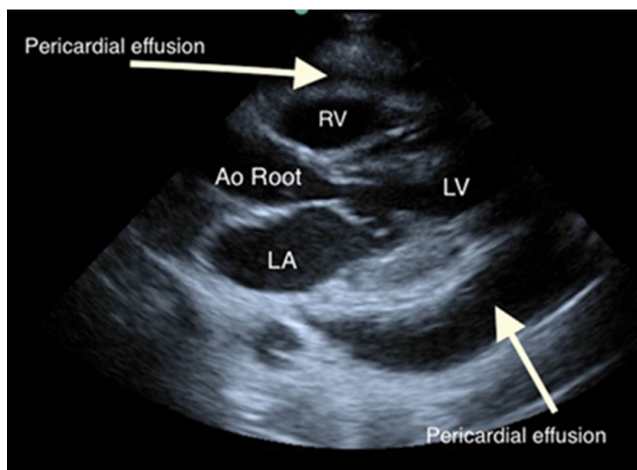


Figure 1. Echocardiogram shows moderate amount of pericardial effusion (white arrows). RV = right ventricle, LV = left ventricle, LA = left atrium, and Ao = aorta.

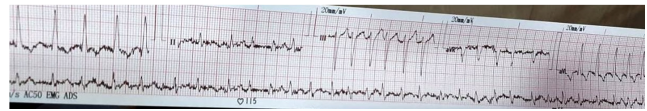

Figure 2. The ECG showed acute rapid atrial fibrillation at presentation.

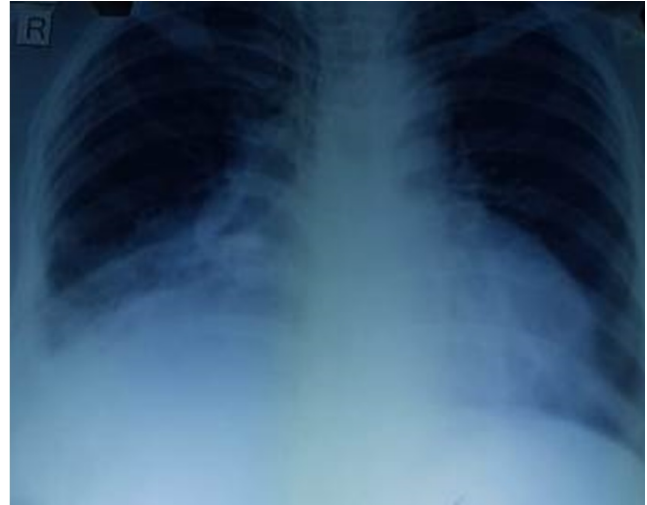

Figure 3. Chest X-ray at presentation shows right-sided pleural effusion and cardiomegaly due to pericardial effusion.

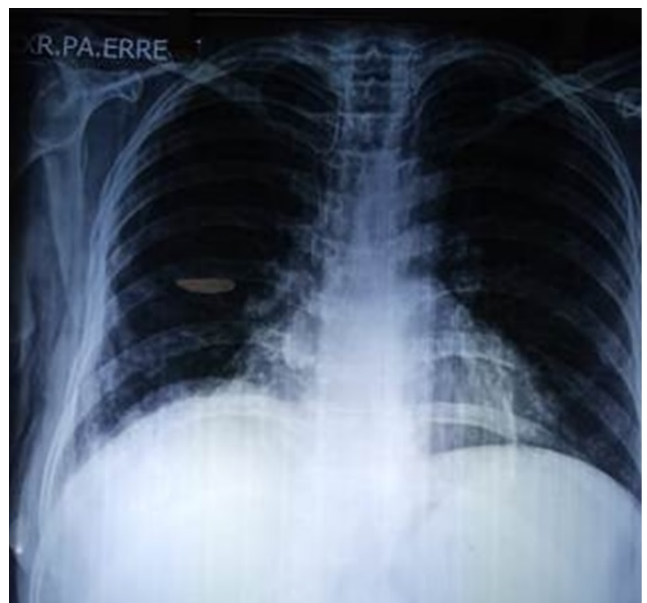

Figure 4. Chest X-ray after treatment shows complete resolution of pleural and pericardial effusions.

diogram. The patient was advised for regular long-life follow-up with intermittent courses of Albendazole to eradicate remnant hepatic cysts and prevention of the appearance of new cysts anywhere in the body. Informed consent from the patient was taken for publishing this case with its associated pictures.

DISCUSSION

This case report represents a rare complication of a ruptured hydatid cyst in the closed space. Therefore, there is no occurrence of an anaphylactic shock accompanying this rupture. Coinciding with this rupture, there were pleural and pericardial effusions. The most possible mechanism of these effusions is the passage of the infection through lymphatic drainage similar to the pathogenesis of these effusions in the case of tuberculosis [5, 6].

The diagnosis of the causes of the pleural and pericardial effusions is difficult, particularly in the case of uncommon presentation as in this case due to a wide range of common causes like tuberculosis, metastatic malignancies, and others. The usual step in the diagnosis of the reasons for these effusions is an aspiration of the fluid which sends for microbiological, biochemical, and cytological examinations. However, in the case of a ruptured hydatid cyst, aspiration from these effusions might lead to catastrophic complications like metastatic hydatid cysts locally and maybe systemically. This was the first challenge that faced us in the management of the presenting case. We put the high possibility of rupturing the remaining small cysts which were left after her previous operation of removal large two hepatic hydatid cysts as a cause of the pleural and pericardial effusions in the presenting case. However, we must exclude a hydatid pleural or pericardial effusion due to cystopericardial or cystopleural fistula or both. This was done through an imaging study, which was confirmed that there was no such connection with our case. The treatment of these fistulae is surgery with an Albendazole tablets cover [4, 7, 8]. Besides, imaging studies were excluded the other possibility of such effusions which is the presence of hydatid

cysts in the pleura and pericardium. Surgery with an Albendazole tablets cover also is the treatment of choice in such conditions [3, 4].

Accordingly, The treatment of this condition as long as there were no above two mentioned complications are medical treatment with an Albendazole tablet 400 mg twice daily for 5 years intermittently according to the protocol of the therapy [1–4]. Albendazole is an active drug against protoscolecous of *Echinococcus granulosus* which can penetrate hydatid cyst layers [9]. Our patient had remnant multiple small hydatid cysts in the liver, which were inoperable and had gotten complicated rupture cyst to closed space, therefore, it is better to remain on Albendazole for long life duration to prevent next complications as well as treatment of the remaining liver hydatid cysts [1–4]. To our best knowledge, this is the first reported case in the world whom presented with hydatid cysts pleural and pericardial effusions and resolved completely by Albendazole tablets.

CONCLUSION

Although hydatid cyst pleuropericardial effusion is rare, a high index of suspicion is of utmost importance to make such a diagnosis. Treatment with Albendazole in an appropriate, effective dose and duration can cure this complication. It doesn't advisable to perform a pericardial or pleural aspiration to avoid transmission of hydatid cyst locally or systemically.

CONFLICT OF INTEREST

The authors declare that there is no conflict of interest.

REFERENCES

- [1] H. Noaman, S. Rawaf, A. Majeed, and A.-M. Salmasi. Hydatid cyst of the heart. *Angiology*, 68(9):765–768, 2017.
- [2] A. K. Paswan, S. Prakash, and R. K. Dubey. Cardiac tamponade by hydatid pericardial cyst: a rare case report. *Anesthesiol. pain Med.*, 4(1), 2014.
- [3] A. Cecconi *et al.* Acute pericarditis secondary to hydatid cyst rupture: diagnosis by multimodality imaging. *Circulation*, 128(18):2073–2074, 2013.
- [4] L. C. El Fihri *et al.* Pericardial effusion reveals an hepatopericardial fistulas of hepatic echinococcosis (a case report). *Cardiovasc. Disord. Med.*, 2019.
- [5] H. N. Eyad and Y. M. Abdulateef. Abnormal presentation of tb patients: anthropological study. *Ann. Trop. Med. Public Heal.*, 22:46–55, 2019.
- [6] Y. M. Aljanabi, S. A. Lafi, and H. N. Eyada. Tb laboratory diagnosis, a comparative study in baghdad, iraq. *Med. Leg. Updat.*, 20(4):855–860, 2020.
- [7] S. Tiwari and R. Pate. Hydatid cyst presenting with massive unilateral pleural effusion. *Ann. Clin. Case Rep.*, 4:1768, 2019.
- [8] W. Feki, W. Ketata, N. Bahloul, S. Msaad, and S. Kamoun. Secondary pleural hydatidosis: Complication of intrapulmonary echinococcosis. *Lung India Off. Organ Indian Chest Soc.*, 31(3):270, 2014.
- [9] S. H. A. Shams-Ul-Bari, A. A. Malik, A. R. Khaja, T. A. Dass, and Z. A. Naikoo. Role of albendazole in the management of hydatid cyst liver. *Saudi J. Gastroenterol. Off. J. Saudi Gastroenterol. Assoc.*, 17(5):343, 2011.