

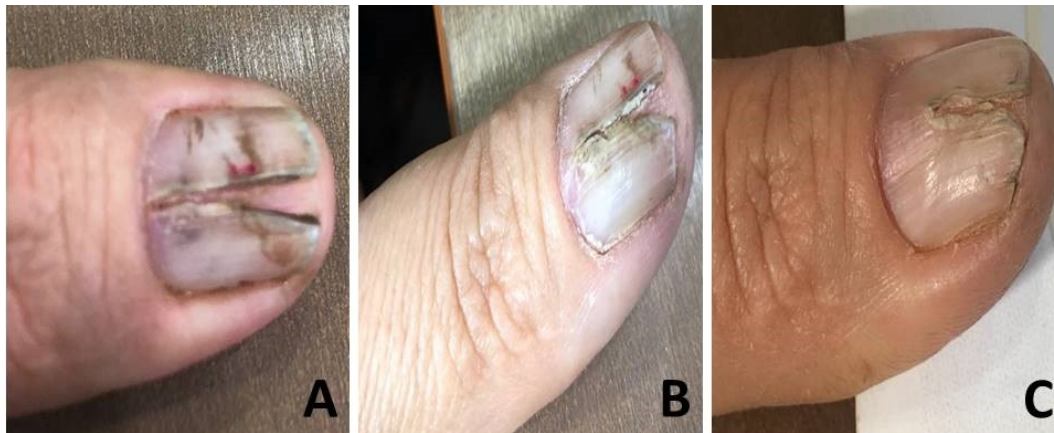
Median Nail Dystrophy

Abdullah Mancy*

Department of Dermatology, Al-Ramadi Teaching Hospital, Anbar Health Directorate, Ramadi, Anbar, Iraq
(Received : 13 March 2020; Accepted : 26 April 2020; First published online: 5 June 2020)

DOI: [10.33091/amj.2020.171052](https://doi.org/10.33091/amj.2020.171052)

© 2020, Al-Anbar Medical Journal



A 35-years-old housewife woman presented with fissuring and yellowish-green discoloration of the central and distal part of the left thumbnail to the Dermatology and Venereology clinic three months ago (Panel A). There was no history of trauma to the nail, no family history of the same condition, and no history of taking drugs. On examination, the left thumbnail had a longitudinal split that extended throughout the entire length of the nail plate, forming a V-shaped configuration. The color of the nail plate was changed mostly to yellowish-green. The nails of the other fingers were normal. Subungual debris and nail clipping were prepared for 10% KOH examination under the microscope but hyphae were not demonstrated. The culture was not available. Median nail dystrophy (MND) consists of longitudinal splitting in the midline of the nail. Thumb is mostly affected. It is of unknown origin, but trauma, familial cases, papilloma, and glomus tumor of the matrix and drugs like isotretinoin and ritonavir, have been reported. Due to color changes of the nail plate, we suspect that dermatophyte infection was the cause of MND. Accordingly, the patient was treated by two pulses of Itraconazole capsules, 200 mg two times per day for one week per month for two successive months. One month after treatment, few mm of a healthy nail appears at the proximal nail fold, (Panel B) and three months, about 1 cm of a normal nail with the disappearance of yellowish discoloration of the nail plate (Panel C). To our best knowledge, the fungal infection doesn't report in the literature as a cause of MND, so fungal infection might be the cause as in this case and further study on this issue is required. The patient now followed-up regularly for 6 months, the time required for the fingernail to replace itself.

* Corresponding author: E-mail: abdmancy@yahoo.com
Phone number: +9647831056564