

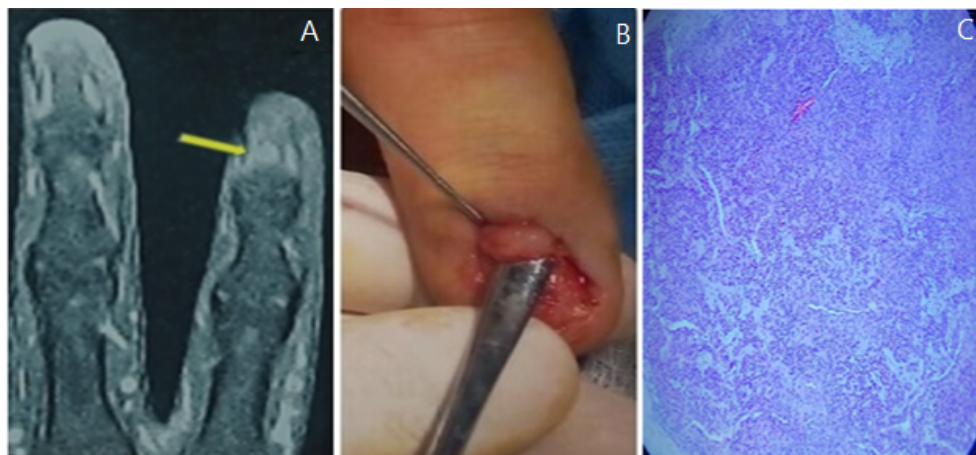
## Subungual Glomus Tumor of the Index Finger

Mohammed J. Alfeehan\*

Department of Surgery (Plastic Surgery), College of Medicine, University of Anbar, Ramadi, Anbar, Iraq  
(Received : 20 May 2019; Accepted : 31 May 2019; First published online: 1 June 2019)

DOI: [10.33091/amj.2019.170889](https://doi.org/10.33091/amj.2019.170889)

© 2019, Al- Anbar Medical Journal



**A** 42-years-old male presented to the plastic outpatient clinic with severe agonizing pain in the fingernail of the right index finger of one-year duration. The pain was aggravated by movement, touch and cold weather, disturbing his sleep and work performance, and not responding to analgesia. On examination, there was only pinpoint tenderness in the lanula of the right index finger with no obvious abnormalities in the phalanx or nail. T2-weighted MRI revealed round, bright lesion subungually in area of lanula about 4 mm in diameter (Panel A) which goes with the diagnosis of the glomus tumor. An excisional biopsy was performed (Panel B). The histopathological study confirmed the diagnosis (Panel C). Glomus tumor is a painful benign tumor of the glomus body (digit thermoregulatory shunt) which accounts for 1–4.5% of tumors in the hand. The tumor characterized by 3 classical features (severe paroxysmal pain, sensitivity to cold, and localized tenderness), most of the affected subjects are suffering from at least two of them. Usually there are no abnormalities in the nail and finger or toe, females are more affected than males. The tumor is treated by surgical excision, but there is a 20% local recurrence rate and metachronous tumors. At follow-up during a one year, the patient reported no pain with some irregularity of the nail.

\* Corresponding author: E-mail: [mjm82anbar@gmail.com](mailto:mjm82anbar@gmail.com)  
Phone number: +9647717724168